Pathology & Oncology Research | frontiers

TYPE Original Research
PUBLISHED 27 November 2026
DOI 10.3389/pore.2026.1612627

Check for updates

OPEN ACCESS

EDITED BY
Anita Árokszállási,
University of Debrecen, Hungary

*CORRESPONDENCE
Norbert Mészáros,
meszaros.norbert@semmelweis.hu

RECEIVED 15 September 2026
REVISED 30 October 2026
ACCEPTED 12 November 2026
PUBLISHED 27 November 2026

CITATION
Mészáros N, Fröhlich G, Vizkeleti J, Heintz Á, Lukács E and Takácsi-Nagy Z (2026) MR-based vaginal vault brachytherapy in endometrial cancer: a dosimetric study.
Pathol. Oncol. Res. 32:1612627.
doi: 10.3389/pore.2026.1612627

COPYRIGHT
© 2026 Mészáros, Fröhlich, Vizkeleti, Heintz, Lukács and Takácsi-Nagy. This is an open-access article distributed under the terms of the Creative Commons Attribution License (CC BY). The use, distribution or reproduction in other forums is permitted, provided the original author(s) and the copyright owner(s) are credited and that the original publication in this journal is cited, in accordance with accepted academic practice. No use, distribution or reproduction is permitted which does not comply with these terms.

MR-based vaginal vault brachytherapy in endometrial cancer: a dosimetric study

Norbert Mészáros [1,2]*, Georgina Fröhlich[2,3], Júlia Vizkeleti[2], Ádám Heintz[4], Edina Lukács[5] and Zoltán Takácsi-Nagy[2,6]

[1]Department of Clinical Oncology, Faculty of Medicine, Semmelweis University, Budapest, Hungary, [2]Center of Radiotherapy, National Institute of Oncology, Budapest, Hungary, [3]Department of Biophysics, Eötvös Loránd University, Budapest, Hungary, [4]Center of Oncological Imaging and Invasive Diagnostics, National Institute of Oncology, Budapest, Hungary, [5]Multidisciplinary Center of Gynecological Oncology, National Institute of Oncology, Budapest, Hungary, [6]Department of Radiotherapy, Faculty of Medicine, Semmelweis University, Budapest, Hungary

Purpose: As de-escalation advances in endometrial cancer, more patients receive vaginal vault brachytherapy (VBT) as their sole adjuvant treatment, making patient-specific planning important. We compared geometry-based, non-image-guided planning with MRI-based anatomy-guided planning on non-contrast 0.55-T magnetic resonance imaging (MRI).

Methods: Twenty-seven consecutive patients were treated with high-dose-rate VBT (single-channel applicator; 5 cm active length; 0.5 cm prescription depth); 25 with a reliably delineable vaginal wall were evaluable. Five received 3 × 7 Gy alone and 22 received 3 × 5 Gy plus pelvic external beam radiotherapy (45 Gy/1.8 Gy with chemotherapy in 6, or 46 Gy/2 Gy in 16). Both the delivered geometry-based plan and a retrospectively re-optimized MRI-based plan were evaluated on the same MRI-defined, tissue-only vaginal-wall CTV (applicator lumen excluded). Paired differences are Hodges–Lehmann estimates with 95% CI (Wilcoxon signed-rank test).

Results: Median tissue-only CTV volume was 17.9 cm^3. The MRI-based plan substantially improved target coverage over the geometry-based plan: V100 90.1% vs. 83.8% (+7.8%, 95% CI 3.9 to 12.9; $p < 0.001$) and D90 100.1% vs. 87.1% (+15.5%; $p < 0.001$), with higher EQD2-D90 (+3.0 Gy; $p = 0.016$). Geometry-based V100 fell below 90% in 21 of 25 patients. The MRI-based plan was more conformal (COIN +0.09; $p < 0.001$) and reduced rectal D2cc (–4.8 Gy; $p < 0.001$); bladder and sigmoid D2cc did not differ. Dog-ear grade correlated with reduced target dose ($\rho = -0.44$; $p = 0.028$).

Conclusion: On the tissue-only vaginal-wall CTV, MRI-based anatomy-guided planning improved target coverage and conformality and reduced rectal dose, whereas the geometry-based protocol frequently undercovered the contoured vaginal-wall target, particularly where apical redundancy (dog ears) was present. These dosimetric findings, from a small single-center cohort, suggest a potential advantage of low-field MRI-based planning that requires confirmation in larger studies; the use of cervical cancer-derived OAR benchmarks and the absence of clinical endpoints preclude conclusions regarding clinical benefit.

KEYWORDS
adjuvant radiotherapy, endometrial cancer, image-based brachytherapy, low-field MRI, vaginal vault brachytherapy

Introduction

The postoperative treatment of endometrial cancer has changed substantially since the major adjuvant-radiotherapy trials of the 1980s and 1990s. Early randomized trials, including those by Aalders et al. [1], PORTEC-1 [2], GOG-99 [3], and ASTEC/EN.5 [4], consistently demonstrated that adjuvant pelvic external beam radiotherapy (EBRT) reduces the locoregional recurrence rate by approximately threefold. However, this improvement in local control did not translate into a reduction in distant metastases or endometrial cancer-specific mortality and was associated with increased toxicity, primarily gastrointestinal. Initially, risk groups were defined solely on clinicopathological criteria: FIGO stage, histological subtype, grade, and depth of myometrial invasion (≤50% or >50%).

The advent of molecular medicine has transformed the classification of endometrial carcinoma. The molecular subgroups incorporated into the ESGO-ESTRO-ESP guidelines (POLEmut, MMRd, NSMP, p53abn) now enable precise prognostic assignment, with the aim of refining individualized treatment and preventing unnecessary overtreatment [5, 6]. The 2025 update of these guidelines incorporated the revised 2023 FIGO staging system, which embeds molecular classification directly into stage assignment [6]. PORTEC-4a exemplifies this transition: in women with high-intermediate risk disease it compared adjuvant treatment guided by a molecular integrated risk profile with standard vaginal vault brachytherapy. Recent results indicate that the individualized strategy was non-inferior, with low 5-year vaginal recurrence rates in both groups (4.5% vs. 1.6%), and the 46% of women in the molecular-profile group who had a favorable profile were spared adjuvant treatment altogether [7]. As such de-escalation becomes more prevalent, extended pelvic irradiation is omitted for an increasing number of patients, and postoperative care is focused on local vaginal vault brachytherapy (VBT).

When whole-pelvic EBRT is omitted, local control relies entirely on VBT, as most vaginal recurrences occur at the vaginal vault [8]. Dosimetry must therefore be precise and patient-specific; any geometric inaccuracy or unfavorable dose distribution can compromise the target dose and jeopardize local control. Image-guided adaptive brachytherapy for cervical cancer has used soft-tissue imaging for years and is well validated, as evidenced by the EMBRACE protocols [9]. In the postoperative vaginal vault setting, however, image-based planning is less established and often relies solely on applicator geometry. This gap motivated our dosimetric evaluation of image-guided, MRI-based anatomy-guided planning for this indication.

International guidelines target the upper vagina. The American Brachytherapy Society recommends treating 3–5 cm along the cylinder, with the dose prescribed either to the surface or to a depth of 5 mm, consistent with the PORTEC-2 approach (21 Gy in three fractions, at 5 mm) [8, 10]. At the National Institute of Oncology, a long-standing protocol prescribes treatment to a uniform 5 cm active length, at 0.5 cm from the surface of a single-channel applicator, which is at the upper end of the accepted 3–5 cm range. This study had two aims. The first was to determine whether MRI-based anatomy-guided planning improves on our image-free, geometry-based planning in CTV coverage, conformality, and the dose to the organs at risk (OARs: bladder, rectum, sigmoid). The second was to establish whether the fixed 5 cm protocol keeps each patient within the organ-at-risk benchmark constraints adopted for this study across the range of individual anatomy. Contouring and MRI-based planning were performed on native (non-contrast) pelvic images acquired on a 0.55-T Siemens Free.Max scanner.

Methods

Patients and treatment

We conducted a single-center, retrospective, within-patient comparative dosimetric study in which each patient served as her own control. Consecutive patients treated with postoperative high-dose-rate vaginal vault brachytherapy between December 2024 and March 2025 were identified from institutional records. For each patient, the delivered conventional plan was retrospectively compared with an MRI-based re-plan generated for the purposes of this dosimetric analysis. The study was approved by the Regional and Institutional Research Ethics Committee of the National Institute of Oncology (approval number OOI-RKEB-00033-1/2026). In total, 27 consecutive patients underwent postoperative vaginal vault HDR brachytherapy at our institution during this period. In two patients the vaginal wall could not be reliably delineated on the MR images; the paired dosimetric analysis was therefore performed on the 25 evaluable patients. Both non-evaluable patients belonged to the EBRT + VBT group, so the evaluable cohort comprised 5 patients treated with VBT alone and 20 treated with EBRT + VBT, including all 6 patients who received concurrent chemotherapy. Eligibility required surgery for histologically confirmed endometrial carcinoma at our institution and a recommendation for postoperative VBT by the institutional gynecologic oncology board; neither FIGO stage nor histological subtype served as an exclusion criterion. Each patient received postoperative vaginal vault HDR brachytherapy using a single-channel, MR-compatible plastic vaginal cylinder applicator (2.5 cm diameter; Elekta Brachytherapy, Veenendaal, Netherlands). Only this single applicator diameter was used. The dose was prescribed to 0.5 cm from the applicator surface, with a 5 cm active length used for source activation and geometric optimization (Oncentra Brachy v4.5.3; Elekta Brachytherapy, Veenendaal, Netherlands). Fractionation followed the institutional indication. Five patients treated with brachytherapy alone received 3 × 7 Gy. The remaining 22 patients received 3 × 5 Gy followed by pelvic external beam radiotherapy; brachytherapy preceded external beam radiotherapy in this sequence. The external beam schedule differed between two subgroups: 6 patients received 45 Gy in 1.8 Gy fractions with concurrent chemotherapy according to the PORTEC protocol, and 16 patients received 46 Gy in 2 Gy fractions without chemotherapy.

Imaging and contouring

A single non-contrast pelvic MRI examination per patient was acquired with the MR-compatible single-channel applicator *in situ* and retrospectively retrieved for this analysis; no per-fraction or

adaptive imaging was performed. Images were obtained on a low-field 0.55 T Siemens Free.Max scanner (Siemens Healthineers, Erlangen, Germany) using a body coil and a T2-weighted sequence in the axial and sagittal planes with 1.5 mm slice thickness, reconstructed with a deep-learning algorithm (Deep Resolve Boost) to improve the signal-to-noise ratio at low field. No intravenous contrast was administered, and the applicator was fixed to the patient's thighs with adhesive tape. The delivered brachytherapy source path was reconstructed on the MR images using the manufacturer's applicator library. Together with a radiologist experienced in gynecology, the CTV—comprising the vaginal vault and the full-thickness vaginal wall along the 5 cm active length, with the applicator lumen excluded so that the CTV represented tissue only—and the organs at risk (bladder, rectum, sigmoid, and adjacent bowel loops) were contoured on these images. Both the delivered geometry-based plan and the re-optimized MRI-based plan were then evaluated on this same tissue-only CTV.

Treatment planning and statistical analysis

The delivered geometry-based (non-image-guided) plan had been generated without any imaging or contours, using a fixed geometric prescription (5 cm active length, dose prescribed to 0.5 cm depth). For the present analysis, an MRI-based anatomy-guided plan was then generated by manual graphical re-optimization on the delineated volumes in Oncentra Brachy. To ensure reproducibility and comparability across patients, the same procedure was followed for every patient, with the primary objective of achieving a CTV V100 of 90%; within this objective, organ-at-risk doses were reduced as far as possible. No dwell-time constraints or smoothing restrictions were applied to the dwell-time distribution during re-optimization. Both the delivered geometry-based plan and the re-optimized 3D plan were subsequently evaluated retrospectively on the same MRI-defined contour set by calculating the following dose–volume parameters: CTV coverage (V100, D90), dose homogeneity (DNR [11]), conformality (COIN [12]), and the D2cc of each OAR. Doses were converted to the equivalent dose in 2 Gy fractions (EQD2) using the linear-quadratic model ($\alpha/\beta = 10$ Gy for the target, 3 Gy for late-responding OARs) [13]. For patients who also received pelvic external beam radiotherapy, the EQD2 values for both the target and the organs at risk represent the cumulative dose from both modalities; reported values are medians of the 25 evaluable patients. In accordance with GEC-ESTRO recommendations, the external beam contribution to the cumulative D2cc of each organ at risk was determined by assuming that the most exposed 2 cm^3 received the full external beam prescription dose homogeneously. This contribution was converted to EQD2 using the linear-quadratic model ($\alpha/\beta = 3$ Gy) and summed directly with the EQD2 values of the brachytherapy fractions. The target dose was summed in the same way, adding the full external beam prescription dose converted to EQD2 with $\alpha/\beta = 10$ Gy. Because no deformable dose accumulation was performed, this summation is a conservative estimate. No organ-at-risk dose constraints have been established for adjuvant vaginal vault brachytherapy [14]. We therefore adopted, as a benchmark, the cervical cancer-derived organ-at-risk D2cc planning aims of the EMBRACE II protocol [9], together with the dose–volume reporting framework of ICRU 89 [13], recognizing that these planning aims have not been validated for the postoperative vaginal setting. These aims were developed for definitive chemoradiotherapy of the intact cervix; they served only as preliminary reference benchmarks, and comparisons of absolute values against them should be interpreted with caution. The two plans were compared using the Wilcoxon signed-rank test (Statistica 12.5; StatSoft, Tulsa, OK, USA). Because the data were not normally distributed, results are summarized as median (interquartile range) with the range, and paired differences between plans are expressed as Hodges–Lehmann estimates with 95% confidence intervals. As the external beam contribution to each organ at risk was identical for both plans within a patient, it cancels in the paired difference; the paired analysis was therefore performed on all 25 evaluable patients irrespective of treatment group, whereas absolute EQD2 values are reported separately for the two treatment groups. This was an exploratory analysis; no correction for multiple comparisons was applied, and interpretation emphasizes effect sizes and confidence intervals rather than significance thresholds. No formal sample-size calculation was performed; all consecutive eligible patients treated during the study period were included.

Results

Target coverage and homogeneity

The median tissue-only CTV volume was 17.9 cm^3 (IQR 16.6–21.6; range 11.1–25.3). Both plans were evaluated on this same MRI-defined vaginal-wall CTV.

On the tissue-only CTV, the MRI-based anatomy-guided plan achieved markedly better target coverage than the geometry-based plan. Median V100 was 90.1% (IQR 90.0–90.2) for the MRI-based plan versus 83.8% (IQR 73.2–86.5; range 50.6–100) for the geometry-based plan (Hodges–Lehmann +7.8%, 95% CI 3.9 to 12.9; $p < 0.001$); median D90 was 100.1% versus 87.1% of the prescription (Hodges–Lehmann +15.5%, 95% CI 6.9 to 23.9; $p < 0.001$). The geometry-based coverage was widely dispersed and tended to be lower in larger CTVs, although this trend did not reach statistical significance (Spearman $\rho = -0.36$ for V100, $p = 0.08$; $\rho = -0.40$ for D90, $p = 0.05$): its V100 fell below 90% in 21 of 25 patients and below 80% in 10, whereas the MRI-based plan was at or near the 90% target in nearly all patients (median 90.1%, range 83.5–90.4; 22 of 25 ≥ 90%). Correspondingly, the biologically equivalent target dose was higher with the MRI-based plan (median EQD2-D90 63.0 vs. 59.2 Gy; Hodges–Lehmann +3.0 Gy, 95% CI 0.4 to 5.7; $p = 0.016$). Dose non-uniformity differed only marginally (median DNR 0.57 for both; Hodges–Lehmann −0.01; $p = 0.02$).

Conformality and organ-at-risk doses

Conformality was clearly higher for the MRI-based plan (median COIN 0.30 vs. 0.21; Hodges–Lehmann +0.09, 95% CI 0.08 to 0.10; $p < 0.001$). Among the organs at risk, the rectum showed the largest and most consistent benefit, with a lower D2cc under the MRI-based plan (Hodges–Lehmann −4.8 Gy, 95% CI −6.3 to −3.5; $p < 0.001$); the geometry-based plan exceeded the 65 Gy rectal benchmark in 6 of the 20 EBRT + VBT patients (65.5–68.5 Gy), whereas the MRI-based plan did not. In contrast, the

TABLE 1 Dosimetric comparison of the geometry-based (non-image-guided) and MRI-based (anatomy-guided) plans, both evaluated on the same MRI-defined, tissue-only vaginal-wall CTV (applicator lumen excluded; 25 evaluable patients).

Parameter	Geometry-based, median (IQR) [range]	MRI-based, median (IQR) [range]	Δ (MRI-based – geometry-based), HL [95% CI]	p
Panel A — target coverage, homogeneity and conformity (n = 25)				
CTV volume (cm^3)	17.9 (16.6–21.6) [11.1–25.3]	17.9 (16.6–21.6) [11.1–25.3]	–	–
V100 (%)	83.8 (73.2–86.5) [50.6–100]	90.1 (90.0–90.2) [83.5–90.4]	+7.8 [3.9, 12.9]	<0.001
D90 (%)	87.1 (64.6–95.7) [45.6–129]	100.1 (100.0–100.3) [82.8–101]	+15.5 [6.9, 23.9]	<0.001
DNR	0.57 (0.57–0.58)	0.57 (0.55–0.57)	−0.01 [−0.01, 0.00]	0.02
Conformity index (COIN)	0.21 (0.17–0.23)	0.30 (0.27–0.32)	+0.09 [0.08, 0.10]	<0.001

Parameter	Δ (MRI-based – geometry-based), HL [95% CI]	p	VBT-alone (n = 5) geom./MRI	EBRT + VBT (n = 20) geom./MRI
Panel B — equivalent dose (EQD2, Gy): paired comparison (n = 25); absolute values by treatment group (median [range])				
Target EQD2-D90	+3.0 [0.4, 5.7]	0.016	22.4 (16–43)/29.8	61.8 (51–70)/64.8
Bladder D2cc	−0.9 [−2.3, 3.8]	0.51	29.8 (26–34)/30.6	60.3 (50–67)/60.5
Rectum D2cc	−4.8 [−6.3, −3.5]	<0.001	33.3 (16–40)/27.2	63.5 (53–68)/59.1
Sigmoid D2cc	−0.1 [−1.6, 1.0]	0.75	24.0 (13–43)/24.8	54.7 (45–68)/55.0

Values are median (interquartile range) [range]. The paired difference (Δ = MRI-based – geometry-based) is the Hodges–Lehmann estimate with 95% confidence interval; for organ-at-risk dose a negative value indicates a lower dose, and for coverage/conformity a positive value favors the MRI-based plan. The external beam contribution cancels within each patient, so the paired comparison uses all evaluable patients, whereas absolute EQD2 values are shown by treatment group. This was an exploratory analysis; comparisons are reported without correction for multiple testing, with emphasis on effect sizes and confidence intervals.

differences for the bladder (Hodges–Lehmann −0.9 Gy, 95% CI −2.3 to 3.8; p = 0.51) and sigmoid (−0.1 Gy, 95% CI −1.6 to 1.0; p = 0.75) were not significant, reflecting the fact that re-optimization prioritized target coverage, which at times required maintaining rather than reducing bladder and sigmoid dose. Absolute EQD2 values differed markedly between treatment groups, as expected: in the VBT-alone group the organ-at-risk doses reflected brachytherapy only, whereas in the EBRT + VBT group they represented the cumulative dose (Table 1). In the combined group, all cumulative organ-at-risk doses remained within the cervical cancer-derived benchmark constraints, except for the rectal exceedances with the geometry-based plan noted above. Table 1 summarizes the results, and representative isodose distributions for the two plans are shown in Figure 1.

Postsurgical anatomy at the vaginal apex

On the MR images the applicator was in close contact with the vaginal mucosa in every patient, and no air gaps of clinically relevant size were seen. Apical tissue redundancies (so-called dog ears), defined as apical tissue extending ≥10 mm beyond the applicator surface [15], were identified in 12 of the 25 evaluable patients (48%) and varied in size, part of the redundant tissue lying outside the prescription isodose (Figure 2). The degree of apical redundancy correlated with reduced target dose: with the geometry-based plan, dog-ear grade was inversely associated with EQD2-D90 (Spearman ρ = −0.44, p = 0.028); a similar association persisted with the MRI-based plan (ρ = −0.48, p = 0.015), indicating that apical redundancy challenges coverage regardless of technique.

Discussion

Local control is the central aim of adjuvant treatment in this setting: when adjuvant treatment is omitted, recurrences concentrate at the vaginal vault, typically in the upper third of the vagina [8]. PORTEC-1 and GOG-99 showed that adjuvant pelvic radiotherapy reduces locoregional relapse without prolonging survival [2, 3], and PORTEC-2 subsequently showed that vault brachytherapy is equivalent to pelvic EBRT for vaginal control while producing considerably less late gastrointestinal toxicity [8]. For this reason, VBT rather than external beam radiotherapy has become a standard postoperative treatment option for appropriately selected patients with intermediate- and high-intermediate-risk disease.

The extent of the treated region is determined by vaginal lymphatic drainage: the upper two-thirds drain primarily to the deep pelvic nodes (internal iliac, external iliac, obturator), while the lower third drains to the inguinal nodes. Given that recurrences predominantly occur at the vaginal apex and within the submucosal network, international guidelines confine adjuvant treatment to the upper part of the vagina [10]. The dose is prescribed at 5 mm tissue depth for two reasons: residual tumor cells and vaginal lymphatic

10.3389/pore.2026.1612627

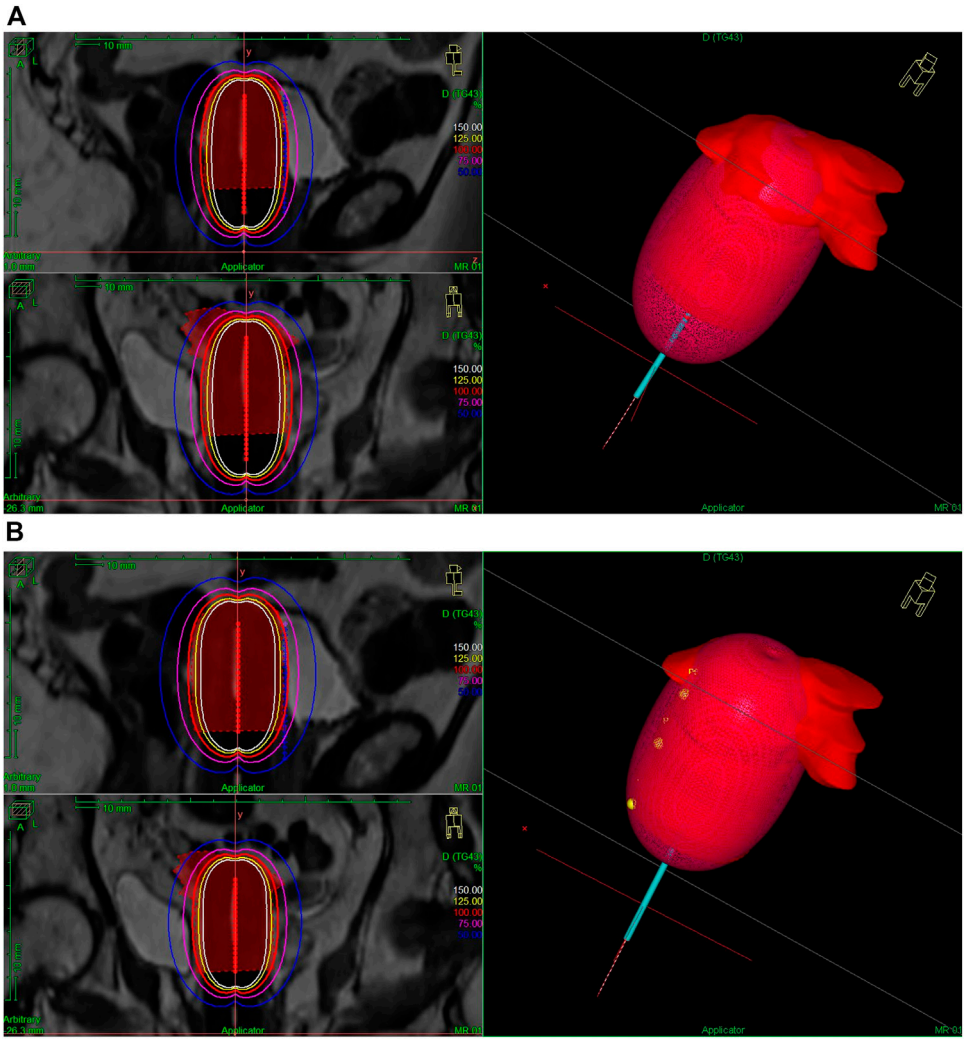

FIGURE 1
Dose distributions of the geometry-based **(A)** and MRI-based anatomy-guided **(B)** plans in the same representative patient. Each panel shows T2-weighted 0.55-T MR images with the single-channel applicator *in situ*, overlaid with the contoured vaginal-wall clinical target volume and the isodose lines (white 150%, yellow 125%, red 100%, magenta 75%, blue 50% of the prescribed dose), together with a three-dimensional rendering of the corresponding dose distribution. Compared with the geometry-based plan **(A)**, the MRI-based plan **(B)** conforms more closely to the target, with tighter high-dose isodoses and less dose spread into the surrounding tissue.

channels lie mostly within a few millimeters of the surface, and the dose from an Ir-192 source decreases sharply with depth, so that a deeper prescription would overdose the vaginal mucosa. Five millimeters therefore represents a practical compromise between target coverage and surface dose [10].

Dosing protocols vary significantly across centers, with differences in prescribed dose, fractionation, treated length, and reference point (surface or 5 mm) [10, 16]; the prescription and optimization strategy itself systematically influences the resulting dose–volume parameters, and the evaluation of vaginal CTV D90 and D2cc is becoming an increasingly important research direction [17]. Some groups prescribe 21 Gy in three fractions at 5 mm [18], while others vary the dose per fraction [19] or prescribe to the mucosal surface. Treatment of the upper third of the vagina, typically 3–4 cm, is widely used, while the American Brachytherapy Society endorses an active length of 3–5 cm [16]; the 5 cm length fixed for historical reasons at the National Institute of Oncology is therefore at the upper end of accepted practice rather than outside it. On the tissue-only vaginal-wall CTV, the MRI-based anatomy-guided plan improved target coverage (V100 and D90), delivered a higher biologically equivalent target dose, was more conformal (COIN), and reduced rectal dose. The key dosimetric finding is that the geometry-based plan undercovered the contoured vaginal-wall target: because it delivers a fixed dose to a fixed depth regardless of individual anatomy, it fails to cover the parts of the vaginal wall that lie beyond that geometry—most notably the apical redundancies (dog ears), whose grade correlated with reduced target dose. Coverage of a larger CTV by an applicator of fixed diameter is inherently more difficult: larger target volumes typically reflect apical redundancies and tissue above the tip of the applicator, which a single-channel cylinder can reach only by increasing the dwell times at the tip, and thus at the cost of a higher rectal dose.

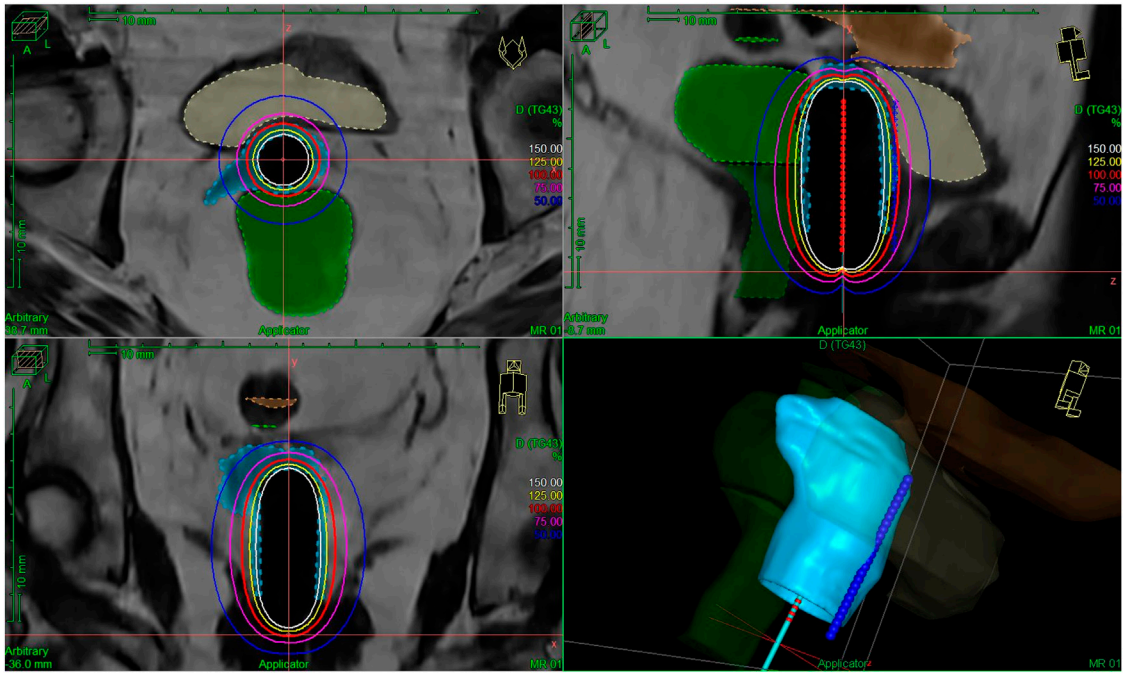

FIGURE 2
Apical tissue redundancy ("dog ear") at the vaginal vault on a non-contrast T2-weighted 0.55-T MR image with the single-channel applicator in place. The redundant apical tissue extends beyond the surface of the applicator, so that part of it lies outside the region covered by the prescription isodose; such dog ears were present in 12 of the 25 evaluable patients (48%).

Anatomy-guided optimization corrected this, raising V100 to the protocol target in nearly all patients. The bladder and sigmoid showed no significant change, because optimization prioritized coverage and at times had to maintain their dose to achieve it; the rectum, the most exposed organ, could nonetheless be spared. Importantly, this coverage gain was not obtained at the expense of the organs at risk: neither the bladder nor the sigmoid dose increased significantly (both confidence intervals included zero rather than shifting toward higher dose), so the improved target coverage and the lower rectal dose were achieved without a measurable dosimetric penalty to the other organs. The rectal dose reduction is a cohort-level finding (median paired difference −4.8 Gy) and does not exclude that individual geometry-based plans exceeded the rectal benchmark, as observed in 6 of the 20 EBRT + VBT patients. This finding is consistent with the study by Gultekin et al. [20], which also reported a modest but consistent difference in conformality and organ-at-risk dose between 2D and MRI-based planning. Chapman et al. [21] further showed that a uniform 5 mm prescription depth may not suit every patient, given the variable thickness of the vaginal wall. Our finding that geometry-based planning undercovered the vaginal wall may appear to contrast with earlier dosimetric comparisons, in which point- or geometry-based plans achieved adequate coverage (D90 ≥ 95%) and image-based planning improved mainly organ-at-risk sparing [22, 23]. This discrepancy is explained by how the target is defined: those studies delineated the CTV as a geometric expansion of the applicator (typically the upper cylinder plus a 5 mm margin), which is well covered by the cylinder dose by construction. When the true, full-thickness vaginal wall is contoured instead, as here, the fixed geometry no longer conforms to individual anatomy and undercoverage emerges. This is consistent with the MRI-based analysis of Chapman et al. [21], who found that over two-thirds of patients had at least 1 cm^3 of the vaginal cuff receiving less than 75% of the prescription dose—undetectable on CT—largely because undistended vaginal tissue and suture material prevented full cylinder apposition. The apparent adequacy of geometry-based planning is therefore a function of the target definition rather than of the dose actually delivered to the tissue.

These findings require careful interpretation. The geometry-based protocol prescribes the dose to a depth of 5 mm from the applicator surface, whereas the CTV used here comprised the full-thickness vaginal wall delineated on MRI, which in places, particularly in apical redundancies, extends beyond that depth. The lower V100 of the geometry-based plan therefore indicates reduced coverage of this retrospectively defined anatomical target, not inferior clinical outcomes: conventional VBT achieved a 5-year vaginal recurrence rate of 1.8% in PORTEC-2 [8], and no dose–response relationship between vaginal-wall CTV dose and vaginal control has been established for adjuvant VBT. Because vaginal recurrence is rare, a comparison of planning techniques powered for vaginal control would require several thousand patients, so dose–volume analysis is a necessary first step. Whether the improved anatomical coverage, which was concentrated at the apex where most vaginal recurrences arise [8, 15], translates into a clinical benefit can only be determined in prospective studies with local control and toxicity endpoints.

The accuracy of postoperative VBT is frequently complicated by postsurgical anatomy. Following removal of the uterus, adnexa, and lymph nodes, the vaginal vault lies close to the rectum, the

posteroinferior bladder wall, and bowel loops, and irregularities are common along the suture line, such as air gaps between the applicator and the mucosa, and tissue redundancies at the apex (so-called dog ears). Richman et al. identified air gaps in 82% of post-insertion images; however, these were minor and did not worsen vault recurrence, with a 5-year freedom from vaginal cuff failure of 96% [24]. Venner et al. reported dog ears in 57.5% of patients; relapse did not differ significantly (7.1% vs. 4.3%, $p = 0.56$), although the absolute number of recurrences almost doubled, which warrants caution in high-grade tumors [15]. We identified similar apical redundancies in our own cohort, although somewhat lower (48% of evaluable patients; Figure 2); this difference may reflect the use of MRI rather than CT for assessment, as well as differences between the populations. Interpreted together with our dosimetry, this indicates that the present dosimetric study cannot determine whether MRI-based planning affects local control; its immediately demonstrable value lies in patient-specific documentation of target coverage and organ-at-risk exposure.

Our analysis was based on a single MRI per patient, acquired with the applicator *in situ* before the first fraction; no further MRI was performed, and all three fractions were delivered with the geometry-based plan. The optimized MRI-based plan was therefore assumed to apply to all three fractions. Interfraction variation may limit this assumption in two ways. First, differences in applicator insertion depth or angle shift the dose distribution relative to the vaginal apex; this matters most for an anatomy-guided plan, whose dwell-time pattern is tailored to apical tissue redundancies, and less for a symmetric geometry-based plan. Second, bladder and rectal filling change the position of the organs at risk relative to the applicator, so organ-at-risk D2cc values from a single image represent one snapshot rather than the delivered dose. In practice, these uncertainties can be reduced by a standardized bladder-filling and bowel-preparation protocol, reproducible fixation of the applicator, and verification of insertion depth before each fraction. Repeat imaging before later fractions, at least in patients with marked apical redundancy, would allow re-optimization when the anatomy has changed, and the easier access of a low-field scanner may make such imaging more practicable. The magnitude of interfraction variation on low-field MRI should be quantified in a prospective study with per-fraction imaging.

The principal novelty of this work lies in the imaging platform. Image-based vault brachytherapy has almost always relied on CT, and where MRI is used, it is generally performed at 1.5 or 3 T. In this cohort, target and organ-at-risk delineation and MRI-based planning were feasible on a 0.55-T low-field system in the evaluable patients. Potential practical advantages of low-field MRI include a wider bore, lower infrastructure requirements, and reduced susceptibility-related artifacts near the applicator; whether these translate into a meaningful benefit in the brachytherapy setting requires further evaluation. More broadly, these findings fit the ongoing shift toward image-guided, anatomy-adapted vaginal brachytherapy—MRI-based target definition, automated segmentation, and MR-guided workflows—in which soft-tissue contrast is used to visualize the vaginal wall and apical redundancies that CT and geometry-based planning miss; our contribution is to show that this is feasible, in a small cohort, on a more accessible low-field platform.

Compared with the geometry-based workflow, which requires no imaging or contouring, MRI-based planning adds several steps: an MR-compatible applicator and a validated applicator library for source-path reconstruction; one MRI acquisition with the applicator *in situ* (approximately 20 min, including positioning); delineation of the vaginal-wall CTV and organs at risk, which in our experience required the input of a radiologist experienced in gynecological imaging (approximately 25 min per patient initially, decreasing to about 15 min with experience); and graphical optimization and plan review (15–20 min, decreasing to under 15 min in the last patients); these times are estimates and were not formally measured. The patient must also be transferred to the scanner with the applicator in place, which requires reproducible fixation. A low-field system may lower some of these barriers: the 0.55-T scanner used here has a wide (80 cm) bore, and its lower siting and infrastructure requirements may allow installation close to or within a radiotherapy department. Its lower signal-to-noise ratio was partly compensated by deep-learning reconstruction but remains a potential limitation for delineation. Given the additional workload, MRI-based planning may be implemented first for patients treated with VBT alone and for those with unfavorable apical anatomy, in whom a coverage deficit of the geometry-based plan would be most consequential.

Limitations

This was a retrospective single-center dosimetric study based on re-planning of imaging and treatment data from 27 consecutive patients, of whom 25 were evaluable. Local control, toxicity, and long-term clinical outcomes were not assessed; the findings are therefore hypothesis-generating rather than definitive. The MRI-based plans were optimized retrospectively towards a V100 of 90% on the same contours on which they were evaluated, which favors them by design; the comparison therefore quantifies how far the geometry-based plan falls short of an achievable anatomical target, and the magnitude of the improvement should be interpreted accordingly. Only a single cylinder diameter (2.5 cm) was used, so the results may not apply to other applicator sizes or types. The cohort was histologically mixed, which reflects routine practice but reduces the homogeneity of the comparison. Treatment was also heterogeneous: of the 25 evaluable patients, 20 received additional pelvic external beam radiotherapy (6 with concurrent chemotherapy), so absolute organ-at-risk EQD2 values combine cumulative and brachytherapy-only doses and are therefore reported separately by treatment group. Because the external beam contribution is identical for both plans within a patient, it does not affect the paired comparison. For mobile bowel loops the most exposed 2 cm^3 may lie at different locations in the two plans, so their D2cc difference was not interpreted. The cervical cancer-derived benchmarks and the simple summation of external beam and brachytherapy doses further limit the interpretation of absolute cumulative values. Contouring was carried out by a single radiologist, so interobserver variability could not be assessed. Only one MRI was acquired per patient, so interfraction variation in applicator position and organ filling was not assessed, and the comparison assumes the same anatomy for all fractions. Finally, the lower signal-to-noise ratio and spatial resolution of 0.55-T low-field MRI compared with high-field

systems may limit the accuracy of soft-tissue delineation, which warrants dedicated study.

Conclusion

In a gynecologic oncology that increasingly relies on molecular tumor profiling (risk stratification along the PORTEC-4a lines) and the de-escalation of pelvic irradiation, the precise delivery of VBT is gaining importance, as it may become the sole adjuvant treatment for a growing number of patients. On these data, the geometry-based protocol used at our institution—a 5 cm active length with the dose prescribed to 0.5 cm—undercovered the contoured vaginal-wall target in most patients (V100 below 90% in 21 of 25), particularly where apical redundancy was present, while generally remaining within the cervical cancer-derived GEC-ESTRO/EMBRACE organ-at-risk benchmark constraints, with rectal benchmark exceedances in 6 of the 20 EBRT + VBT patients. MRI-based anatomy-guided planning achieved the intended target coverage, improved conformality, and reduced rectal dose. This suggests that image guidance may be most useful in ensuring reproducible target coverage across variable post-surgical anatomy. The additional conformality and organ-at-risk sparing offered by MRI-based planning are likely to be of greatest value in documenting a patient-specific plan; MRI-based planning may be particularly useful in anatomically unfavorable cases, although this hypothesis requires prospective evaluation. These observations derive from a small, single-center, retrospective series of 25 evaluable patients and should be regarded as hypothesis-generating; larger, preferably multicenter studies are needed to confirm them. The clinical relevance of the improved target coverage and rectal sparing has not been established: whether they translate into better vaginal control or lower toxicity can be determined only by prospective studies with clinical endpoints.

Data availability statement

The raw data supporting the conclusions of this article will be made available by the authors, without undue reservation.

Ethics statement

The studies involving humans were approved by the Regional and Institutional Research Ethics Committee, National Institute of Oncology, Budapest, Hungary (Országos Onkológiai Intézet Regionális, Intézményi Tudományos és Kutatásetikai Bizottság; approval number OOI-RKEB-00033-1/2026) as a non-interventional, retrospective study. The studies were conducted in accordance with the local legislation, institutional requirements and the Declaration of Helsinki. The participants provided their written informed consent for the use of their clinical and imaging data for research, in accordance with institutional requirements.

Author contributions

NM: conceptualisation, methodology, project administration, writing – original draft, data interpretation. GF: methodology, software, formal analysis (dosimetric and statistical), validation, visualization, writing – review and editing. JV: patient treatment and management, data interpretation, writing – review and editing. ÁH: investigation (MR imaging and contouring), data curation, writing – review and editing. EL: resources (surgical and gynecologic oncology care), writing – review and editing. ZT-N: supervision, writing – review and editing. All authors contributed to the article and approved the submitted version.

Funding

The author(s) declared that financial support was not received for this work and/or its publication.

Conflict of interest

The author(s) declared that this work was conducted in the absence of any commercial or financial relationships that could be construed as a potential conflict of interest.

Generative AI statement

The author(s) declared that generative AI was used in the creation of this manuscript. During the preparation of this work, the authors used generative AI tools for English-language editing and for checking the statistical calculations. Specifically, Gemini (Google) was used for language editing and readability, and Claude (Anthropic) was used only to check the statistical calculations. All statistical analyses were performed by a medical physicist (GF) using Statistica 12.5 (StatSoft, Tulsa, OK, USA). These tools were not used to generate primary study data or to develop the scientific conclusions. All AI-assisted content and analyses were critically reviewed and verified by the authors, who take full responsibility for the final content of the published article.

Any alternative text (alt text) provided alongside figures in this article has been generated by Frontiers with the support of artificial intelligence and reasonable efforts have been made to ensure accuracy, including review by the authors wherever possible. If you identify any issues, please contact us.

References

1. Aalders J, Abeler V, Kolstad P, Onsrud M. Postoperative external irradiation and prognostic parameters in stage I endometrial carcinoma: clinical and histopathologic study of 540 patients. *Obstet Gynecol* (1980) 56(4):419–27.

2. Creutzberg CL, van Putten WL, Koper PC, Lybeert ML, Jobsen JJ, Wárlám-Rodenhuis CC, et al. Surgery and postoperative radiotherapy versus surgery alone for patients with stage-1 endometrial carcinoma: multicentre randomised trial.

PORTEC Study Group. (2000) 355(9213):1404–11. doi: 10.1016/S0140-6736(00)02139-5

3. Keys HM, Roberts JA, Brunetto VL, Zaino RJ, Spirtos NM, Bloss JD, et al. A phase III trial of surgery with or without adjunctive external pelvic radiation therapy in intermediate risk endometrial adenocarcinoma: a Gynecologic Oncology Group study. *Gynecol Oncol* (2004) 92(3):744–51. doi: 10.1016/j.ygyno.2003.11.048

4. ASTEC/EN.5 Study Group, Blake P, Swart AM, Orton J, Kitchener H, Whelan T, et al. Adjuvant external beam radiotherapy in the treatment of endometrial cancer (MRC ASTEC and NCIC CTG EN.5 randomised trials): pooled trial results, systematic review, and meta-analysis. *Lancet* (2009) 373(9658):137–46. doi: 10.1016/S0140-6736(08)61767-5

5. Concin N, Matias-Guiu X, Vergote I, Cibula D, Mirza MR, Marnitz S, et al. ESGO/ESTRO/ESP guidelines for the management of patients with endometrial carcinoma. *Int J Gynecol Cancer* (2021) 31(1):12–39. doi: 10.1136/ijgc-2020-002230

6. Concin N, Matias-Guiu X, Cibula D, Colombo N, Creutzberg CL, Ledermann J, et al. ESGO–ESTRO–ESP guidelines for the management of patients with endometrial carcinoma: update 2025. *Lancet Oncol* (2025) 26(8):e423–e435. doi: 10.1016/S1470-2045(25)00167-6

7. van den Heerik ASVM, Horeweg N, Haverkort MAD, Kuijsters N, Kommoss S, Koppe FLA, et al. Molecular profile-based adjuvant treatment for women with high-intermediate risk endometrial cancer (PORTEC-4a): results of a randomised, open-label, phase 3, multicentre, non-inferiority trial. *Lancet Oncol* (2026) 27(1):23–35. doi: 10.1016/S1470-2045(25)00612-6

8. Nout RA, Smit VTHBM, Putter H, Jürgenliemk-Schulz IM, Jobsen JJ, Lutgens LCHW, et al. Vaginal brachytherapy *versus* pelvic external beam radiotherapy for patients with endometrial cancer of high-intermediate risk (PORTEC-2): an open-label, non-inferiority, randomised trial. *Lancet* (2010) 375(9717):816–23. doi: 10.1016/S0140-6736(09)62163-2

9. Pötter R, Tanderup K, Kirisits C, de Leeuw A, Kirchheiner K, Nout R, et al. The EMBRACE II study: the outcome and prospect of two decades of evolution within the GEC-ESTRO GYN working group and the EMBRACE studies. *Clin Transl Radiat Oncol* (2018) 9, 48–60. doi: 10.1016/j.ctro.2018.01.001

10. Harkenrider MM, Block AM, Alektiar KM, Gaffney DK, Jones E, Klopp A, et al. American Brachytherapy Task Group Report: adjuvant vaginal brachytherapy for early-stage endometrial cancer: a comprehensive review. *Brachytherapy* (2017) 16(1):95–108. doi: 10.1016/j.brachy.2016.04.005

11. Saw CB, Suntharalingam N, Wu A. Concept of dose nonuniformity in interstitial brachytherapy. *Int J Radiat Oncol Biol Phys* (1993) 26(3):519–27. doi: 10.1016/0360-3016(93)90974-2

12. Baltas D, Kolotas C, Geramani K, Mould RF, Ioannidis G, Kekchidi M, et al. A conformal index (COIN) to evaluate implant quality and dose specification in brachytherapy. *Int J Radiat Oncol Biol Phys* (1998) 40(2):515–24. doi: 10.1016/S0360-3016(97)00732-3

13. International Commission on Radiation Units and Measurements. ICRU Report 89: prescribing, recording, and reporting brachytherapy for cancer of the cervix. *J ICRU* (2013) 13(1–2). doi: 10.1093/jicru_ndw027

14. Tselepidakis N, Jin R, Horton B, Zheng W, Janowski EM, Romano K. Gastrointestinal and genitourinary toxicity following high dose rate vaginal cuff brachytherapy for endometrial cancer. *Brachytherapy* (2025) 24(3):389–94. doi: 10.1016/j.brachy.2025.02.005

15. Venner EK, Ward KA, Wages NA, Walker B, Libby BP, Showalter TN, et al. Evaluating the relationship between vaginal apex "dog ears" and patterns of recurrence in endometrial cancer following adjuvant image guided vaginal cuff brachytherapy. *Brachytherapy* (2023) 22(2):139–45. doi: 10.1016/j.brachy.2022.10.008

16. Small W Jr, Beriwal S, Demanes DJ, Dusenbery KE, Gaffney DK, Hansen JA, et al. American Brachytherapy Society consensus guidelines for adjuvant vaginal cuff brachytherapy after hysterectomy. *Brachytherapy* (2012) 11(1):58–67. doi: 10.1016/j.brachy.2011.08.005

17. Qiang Y, Noorian F, Abellana R, Baltrons C, Lancellotta V, Tagliaferri L, et al. D90 and D2cc dose in vaginal CTV as dosimetric predictors of late vaginal side effects in postoperative vaginal modern brachytherapy (interventional radiotherapy) after external beam irradiation in endometrial cancer. *Cancers* (2026) 18(14):2350. doi: 10.3390/cancers18142350

18. Laliscia C, Delishaj D, Fabrini MG, Gonnelli A, Morganti R, Perrone F, et al. Acute and late vaginal toxicity after adjuvant high-dose-rate vaginal brachytherapy in patients with intermediate risk endometrial cancer: is local therapy with hyaluronic acid of clinical benefit? *J Contemp Brachytherapy* (2016) 8(6):512–7. doi: 10.5114/jcb.2016.64511

19. Sorbe B, Straumits A, Karlsson L. Intravaginal high-dose-rate brachytherapy for stage I endometrial cancer: a randomized study of two dose-per-fraction levels. *Int J Radiat Oncol Biol Phys* (2005) 62(5):1385–9. doi: 10.1016/j.ijrobp.2004.12.079

20. Gultekin M, Yilmaz MT, Biltekin F, Yuce D, Sari SY, Akyol F, et al. Adjuvant vaginal cuff brachytherapy: dosimetric comparison of conventional *versus* 3-dimensional planning in endometrial cancer. *J Contemp Brachytherapy* (2020) 12(6):601–5. doi: 10.5114/jcb.2020.101694

21. Chapman CH, Prisciandaro JI, Maturen KE, Cao Y, Balter JM, Pantelic MV, et al. MRI-based evaluation of the vaginal cuff in brachytherapy planning: are we missing the target? *Int J Radiat Oncol Biol Phys* (2016) 95(2):743–50. doi: 10.1016/j.ijrobp.2016.01.042

22. Kim H, Kim H, Houser C, Beriwal S. Is there any advantage to three-dimensional planning for vaginal cuff brachytherapy? *Brachytherapy* (2012) 11(5):398–401. doi: 10.1016/j.brachy.2011.12.009

23. Russo JK, Armeson KE, Richardson S. Comparison of 2D and 3D imaging and treatment planning for postoperative vaginal apex high-dose-rate brachytherapy for endometrial cancer. *Int J Radiat Oncol Biol Phys* (2012) 83(1):e75–e80. doi: 10.1016/j.ijrobp.2011.11.029

24. Richman AH, Patel AK, Rodríguez-López JL, Keller A, Vargo JA, Kim H, et al. Do air gaps with image-guided vaginal cuff brachytherapy impact failure rates in patients with high-intermediate risk FIGO stage I endometrial cancer? *Brachytherapy* (2021) 20(3):512–8. doi: 10.1016/j.brachy.2020.11.006