

## ARTICLE

## Magnetic Resonance Imaging of Bone Marrow Versus Bone Marrow Biopsy in Malignant Lymphoma

Mustafa ÖZGÜROĞLU,<sup>1</sup> Gül ESEN ERSAVASTI,<sup>2</sup> Gökhan DEMİR,<sup>1</sup> Hilal AKI,<sup>3</sup> Fuat DEMİRELLİ,<sup>1</sup>  
Kaya KANBEROĞLU,<sup>2</sup> Nil MANDEL,<sup>1</sup> Evin BÜYÜKÜNAL,<sup>1</sup> Süheyla SERDENGEÇTİ,<sup>1</sup> Bülent BERKARDA<sup>1</sup>

<sup>1</sup>Department of Internal Medicine, Medical Oncology Section, <sup>2</sup>Department of Radiology and <sup>3</sup>Department of Pathology, Cerrahpasa Medical School, Istanbul University, Istanbul, Turkey

Bone marrow involvement is a frequent finding in malignant lymphoma. Bone marrow biopsy of the posterior iliac crest is routinely performed for staging. Abnormal magnetic resonance imaging (MRI) signals of bone marrow was also reported to be indicative of bone marrow involvement. This study included 60 patients with malignant lymphoma. Unilateral bone marrow biopsy of the posterior iliac crest was performed. MRI of lumbar spine was studied within 24 hours of bone marrow biopsy. 22 healthy controls were used for the detection of MRI objectivity during visual evaluation. In 83% of patients (50/60), biopsy and MRI results agreed completely. In two patients, histologic sections failed to show any evidence of bone marrow invol-

vement despite abnormal MRI signals suggestive of involvement. In three patients, MRI was completely normal despite biopsy proven bone marrow infiltration. False negativity (3/60) and false positivity (2/60) rates were very low. Negative biopsy findings with positive or equivocal MRI results should not exclude bone marrow involvement and needs further evaluation with bilateral or guided biopsy. Thus, we conclude that MRI of bone marrow is a fairly sensitive, noninvasive modality and might be of potential value in detecting bone marrow infiltration in malignant lymphoid neoplasms which can be utilized as a useful adjunct to standard staging procedures. (Pathology Oncology Research Vol 5, No 2, 123–128, 1999)

*Keywords:* malignant lymphoma, bone marrow biopsy, magnetic resonance imaging

### Introduction

Malignant lymphomas are primary neoplasms of lymphoid tissues, with two different spectrum of diseases; Hodgkin's disease (HD) and non-Hodgkin lymphoma (NHL). Staging in malignant lymphomas which has paramount importance includes physical examination, chest X-ray, computed (CAT) scan of the abdomen and pelvis and bone marrow biopsy.<sup>1,2</sup>

Unilateral blind biopsy of bone marrow of the posterior iliac crest is routinely performed during bone marrow evaluation.<sup>3-5</sup> It is recommended to perform bone marrow

biopsy for all patients with NHL<sup>1</sup> and for patients with stage IIIA or greater in HD.<sup>2</sup> 25–40% of patients with NHL<sup>6</sup> and 5–15% of patients with HD<sup>7,8</sup> have bone marrow involvement. Accurate documentation of the bone marrow status is critical in choosing the appropriate therapeutic strategy. A means of improving the detection of marrow infiltration would therefore have important therapeutic implications.

In order to detect and evaluate the extent of bone marrow infiltration in malignant lymphoma there are some other diagnostic tests such as bone marrow scintigraphy,<sup>9,10</sup> flow cytometric analysis of marrow aspirate (FC)<sup>11</sup> and magnetic resonance imaging (MRI) of bone marrow.<sup>12-14</sup> MRI is an especially promising method in exploring relatively large volumes of marrow non-invasively. It is well suited for examining soft tissues on the basis of different proton densities<sup>15-17</sup> and T1 and T2 relaxation times.<sup>18,19</sup>

*Received:* Febr 12, 1999; *accepted:* April 15, 1999

*Correspondence:* Mustafa ÖZGÜROĞLU, M.D., Yoğurtçu Başı Sokağı, Akçira apt. 20/3, Dalyan – Fenerbahçe 81030, Istanbul, Turkey; Tel: +90-216-3638378, fax: +90-212-5877700, e-mail: ozguroglu@superonline.com –

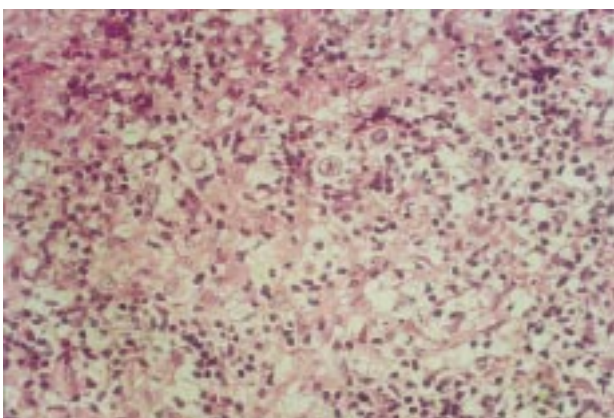
**Table 1. Definitions used for bone marrow biopsy and MRI evaluations**

|                                       |  |
|---------------------------------------|--|
| <i>Findings at bone marrow biopsy</i> | <i>Normal</i>  |
|                                       | <i>Diffuse</i> – all hematopoietic cells were displaced by malignant cells   |
|                                       | <i>Nodular</i> – malignant cells in groups, normal hematopoietic cells disappeared in areas of infiltration              |
|                                       | <i>Interstitial</i> – neoplastic infiltration in the interstitium with normal hematopoietic cells                        |
| <i>Findings at MRI</i>                | <i>Negative</i> – completely normal  |
|                                       | <i>Positive</i> – Diffuse or patchy decreases in intensity in all lumbar vertebrae; highly suggestive of infiltration    |
|                                       | <i>Equivocal</i> – Subtle intensity changes or involvement in only a few vertebrae; suspicious for tumoral infiltration. |

The aim of this study was to assess the ability of MRI to document bone marrow involvement in patients with malignant lymphoma. This study was also undertaken to compare the efficacy of MRI with bone marrow biopsy in the evaluation of bone marrow infiltration.

### Materials and Methods

Sixty patients with malignant lymphoma were studied. The patients ranged in age from 19 to 73 (median, 52 years). There were 33 men and 27 women. Six had Hodgkin's disease, and 54 had non-Hodgkin's lymphoma (low grade, n = 12; intermediate grade, n = 22; high grade, n = 20). Classification of non-Hodgkin's lymphoma was based on



**Figure 1.** Bone marrow biopsy showing atypical mononuclear cell infiltration in non-Hodgkin's lymphoma. x400

Working Formulation.<sup>20</sup> Patients were evaluated prior to initiation of treatment. All patients had received chemotherapy. None of the patients had received radiotherapy.

Unilateral blind bone marrow biopsy of the posterior iliac crest was performed, followed by fixation in formalin, sectioning, and staining of the biopsy specimen. The biopsy specimens were evaluated at the Department of Pathology and were classified as normal, diffuse infiltration, nodular infiltration, and interstitial infiltration (*Table 1, Figure 1*).

MRI examinations of lumbar spine were performed on a 1.0 Tesla imager (Siemens Magnetom Impact) within 24 hours of bone marrow biopsy in all patients. The images were acquired in the sagittal plane using a turbo spin-echo T1 weighted sequence (Repetition time: 600 msec, Echo time: 12 msec). The acquisition matrix was 156x256, and the field of view was 163x260mm. Acquisition was 4. The images were evaluated by two radiologists, each blinded to the biopsy results as well as the other radiologist's findings. MRI results were based on the comparison of vertebral body and disc intensities and grouped into three, as negative (normal MRI) (*Figure 2*), positive (diffuse infiltration) (*Figure 3*) and equivocal (*Table 1*).

In order to test the objectivity of visual evaluation of the bone marrow, the images of the patients were mixed up with those of 22 healthy age-adjusted volunteers with a median age of 50 years (range, 21–69). When the diagnoses of the two radiologists were controversial, the ima-

**Table 2. Definitions for the comparison of MRI and biopsy results**

|         | BM (+) | BM (-) |
|---------|--------|--------|
| MRI (+) | TP     | FP     |
| MRI (-) | FN     | TN     |

BM (+) = Positive bone marrow biopsy; BM (-) = Negative bone marrow biopsy. MRI (+) = MRI highly suggestive for tumoral infiltration; MRI (-) = normal MRI. TP = true positive, FP = false positive, TN = true negative, FN = false negative

**Table 3. Correlation of MRI results with bone marrow biopsy**

|           | BM (+) n | BM (-) n | Total n |
|-----------|----------|----------|---------|
| MRI (+) n | 19       | 2        | 21      |
| MRI (-) n | 3        | 31       | 34      |
| MRI (E) n | 1        | 4        | 5       |
| Total n   | 23       | 37       | 60      |

n = Number of patients; MRI (+) = MRI highly suggestive for tumoral infiltration; MRI (-) = MRI negative for tumoral infiltration; MRI (E) = MRI equivocal for infiltration; BM (+) = Biopsy positive for malignancy; BM (-) = Biopsy negative for malignancy

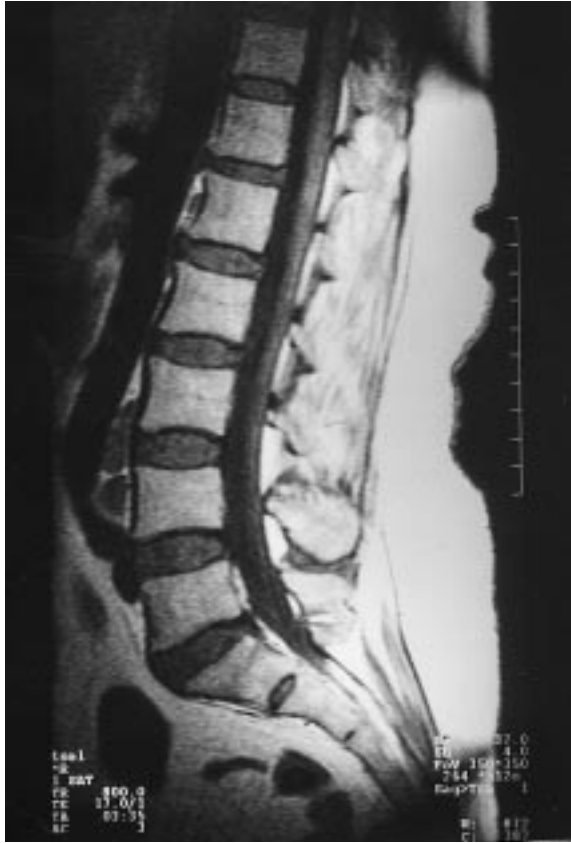

Figure 2. Normal MR findings of bone marrow on T1-weighted images.

ges of that patient were re-evaluated together to reach a final decision.

The definitions underlying the comparison of MRI findings and biopsy results are presented in *table 2*. Sensitivity, specificity, positive and negative predictive values of MRI in detecting bone marrow infiltration were analyzed. Patients with equivocal results in MRI were excluded during statistical evaluation.

### Results

All control cases were correctly diagnosed as negative. None of the patients in the control group showed pathologic signal intensity, demonstrating the objectivity of the two radiologists during visual examination of MRI studies. *Table 3*, presents the correlation of findings at MRI with those at unilateral blind biopsy. Analysis of the results were based on the assumption that the unilateral blind biopsy results were accurate.

In 8% of patients (5/60), MRI findings were evaluated as equivocal (suspicious), as a final decision by two radiologists. Bone marrow biopsies in this group were found to be negative in four patients and positive in one patient (*Table 4*).

With the exception of these patients with equivocal findings, in 90% of patients (50/55), the results of MRI and biopsy agreed completely. Five patients had discordant results between biopsy and MRI. Three patients had negative MRI results despite morphologic involvement of the bone marrow. In contrast, biopsy results of two patients with positive MRI were negative for tumoral infiltration (*Table 3*). Further statistical analysis was performed with the exclusion of equivocal patients. The sensitivity, specificity, positive and negative predictive values of MRI were found to be 90%, 94%, 90% and 91%, respectively.

In 23 patients with positive biopsy results, there was not any correlation between infiltration type and MRI results as seen in *Table 5*. Five with positive, one with equivocal and one with negative MRI results had diffuse bone marrow infiltration. Another six patients with positive and two patients with negative MRI results had nodular type infiltration. Eight patients with negative MRI interpretation were also found to have interstitial type bone marrow infiltration.

There are only six patients with HD evaluated. *Table 6* shows that half of the patients (3/6) had positive MRI and biopsy results (cases 4,5,6). MRI was negative in another

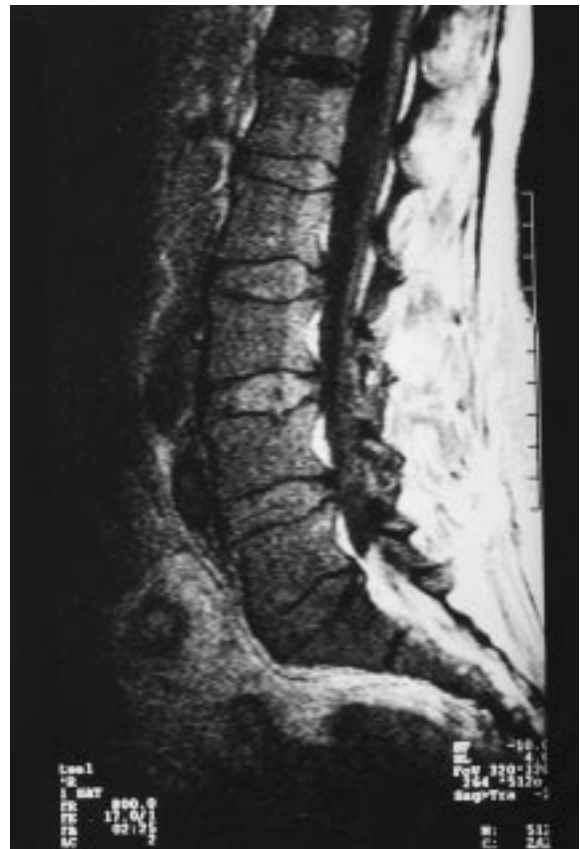

Figure 3. Diffuse signal intensity decrease on T1-weighted images due to diffuse bone marrow infiltration in non-Hodgkin's lymphoma.

**Table 4. Details of MRI with “equivocal” results**

| Cases | Diagnosis              | Bone marrow biopsy   |
|-------|------------------------|----------------------|
| 1     | Hodgkin’s disease      | Negative             |
| 2     | Hodgkin’s disease      | Negative             |
| 3     | Intermediate grade NHL | Negative             |
| 4     | Intermediate grade NHL | Diffuse infiltration |
| 5     | High grade NHL         | Negative             |

**Table 5. Correlation of patterns of bone marrow infiltration with MRI**

|               | Diffuse type infiltration | Nodular type infiltration | Interstitial type infiltration |
|---------------|---------------------------|---------------------------|--------------------------------|
| MRI positive  | 5                         | 6                         | 8                              |
| MRI negative  | 1                         | 2                         | –                              |
| MRI equivocal | 1                         | –                         | –                              |

**Table 6. Summary of results of MRI and bone marrow biopsy in Hodgkin’s disease.**

| Cases | Bone marrow infiltration | Type of infiltration | MRI results |
|-------|--------------------------|----------------------|-------------|
| 1     | Negative                 | –                    | Equivocal   |
| 2     | Negative                 | –                    | Equivocal   |
| 3     | Negative                 | –                    | Negative    |
| 4     | Positive                 | Diffuse              | Positive    |
| 5     | Positive                 | Diffuse              | Positive    |
| 6     | Positive                 | Nodular              | Positive    |

patient with a negative biopsy (case 3). However, two patients had equivocal MRI results despite negative bone marrow biopsy (cases 1 and 2). Considering the equivocal MRI results, 2 of 5 patients with equivocal MRI had HD (cases 1 and 2) (Table 4).

### Discussion

Bone marrow infiltration in malignant lymphoma may be diffuse or focal, often associated with fibrosis, especially in Hodgkin’s disease.<sup>6,8,21</sup> There are several diagnostic methods that can be used for the investigation of bone marrow. Bone marrow involvement can be discovered readily by unilateral blind bone marrow biopsy of the posterior iliac crest, performed with a Jamshidi type needle.<sup>22</sup> This invasive procedure removes a small core of marrow and is subject to sampling errors, particularly in HD that may affect the marrow focally.<sup>8,21</sup> In studies with bilateral biopsies it was shown that positive findings were unilateral in 10–40% of patients.<sup>6,7</sup> Bone marrow involvement can only rarely be demonstrated by the usual marrow aspirate

technique and examination of marrow smears. Many physicians now include flow cytometric immunophenotyping of bone marrow aspirates in the assessment of patients.<sup>11,23</sup> In a series of 273 patients with NHL, Naughton et al.<sup>11</sup> reported that FC was positive in one morphologically negative and in two morphologically suspicious case, thereby adding to the sensitivity in 3 of 273 cases. It was clear in Naughton’s study that FC has a very limited role in the staging of malignant lymphoma.

Bone marrow scintigraphy is another, noninvasive way of investigating marrow. It has the potential to show an expansion of hemopoietically active bone marrow or local defects due to displacement by other infiltrating tissues.<sup>9</sup> However, this method has a low spatial resolution and poor specificity.<sup>10,13</sup>

MR imaging is an alternative and non-invasive method, which allows large volumes of marrow to be examined. Adult hematopoietic bone marrow is composed of approximately 30% fat, contained within adipocytes, and 70% water, contained primarily within blood-forming cellular elements.<sup>24</sup> The balance between the proportions of cellular and fatty elements may alter in the presence of disease.<sup>25</sup> The presence of these two populations of protons in water and fat makes red marrow uniquely suited to MRI.<sup>26</sup> Compared to bone marrow scintigraphy MRI is more sensitive to changes in marrow fat, and gives superior anatomic detail.

Using MRI, bone marrow imaging has been investigated with promising results in aplastic anemia,<sup>27</sup> multiple myeloma,<sup>28,29</sup> acute leukemia<sup>13,27</sup> and malignant lymphomas.<sup>12,13,30</sup> In malignant lymphoma, MRI has been investigated with promising results.<sup>12–14,30</sup> In a prospective study of 107 patients with malignant lymphoma, Linden et al. compared bone marrow biopsy with MRI and scintigraphy. It was found that MRI was superior to scintigraphy and combination of MRI plus biopsy was superior to biopsy alone.<sup>13</sup>

MR imaging with its high sensitivity for detecting bone marrow lesions, has rapidly become the preferred imaging technique for determining the presence of these types of lesions. However, a consensus has not been reached on which MR sequences are best suited for this purpose. Some authors have achieved very satisfactory results with conventional spin echo T1 and T2 weighted sequences,<sup>12,19,31,32</sup> whereas others suggest that sequences that use some form of fat suppression such as short T1 inversion recovery (STIR) or fat saturated T2 weighted imaging are more sensitive.<sup>33</sup> However, as seen in the study of Mirowitz et al. which compares all of these sequences, qualitatively there are no significant differences between T1 weighted and fat suppressed images in lesion detection.<sup>34</sup> The same study also shows that T1 weighted images had fewer motion artifacts, better image uniformity and better overall image quality. Moreover optimal results with fat saturation

require high-field strength systems which may not be accessible everywhere. In our experience we think that T1 weighted spin echo imaging is much more simple, practical and as sensitive as these sequences.

In our study, as well as in Linden's study,<sup>13</sup> all healthy controls were diagnosed correctly with only visual evaluation of images, showing the accuracy of the method used. Differential diagnosis of diffuse low intensity replacement of higher signal intensity marrow fat includes hemolytic anemias and some rare pathologies such as thalassemia, leukemia, lipid storage diseases like gaucher disease, and histiocytic proliferative disease.<sup>35</sup> However, in the context of this study, we think that in a population with known malignant lymphoma, diffuse signal intensity changes can be attributed to involvement of the bone marrow; and that increasing the cost of the examination would not add much to the sensitivity..

Our results indicate that MRI was found to have a high specificity (94%) and sensitivity (90%) in detecting bone marrow infiltration. One of the major problems in our study was the establishment of the true state of the bone marrow, as unilateral blind biopsy is subject to substantial sampling errors and all our analyses were based on the bone marrow status. False negativity of MRI (3/55) was observed in three patients (Table 3). There is some data that diffuse infiltration can not be detected on MRI.<sup>13</sup> However, two patients had interstitial infiltration and one patient had nodular infiltration of NHL. False positive results of MRI in two patients (2/55) might be due to non-homogeneous tumor involvement resulting in false negativity at biopsy or nonmalignant bone marrow changes such as osteomyelosclerosis simulating infiltration at MRI. To evaluate the contribution of false negative findings at biopsy to these results, bilateral biopsy, and even guided biopsy have to be performed. None of the patients in our study had bilateral biopsy, which might have increased the sensitivity and decreased the false positivity of MRI. The same is true for equivocal MRI results (Table 4). Four out of 5 patients with equivocal MRI findings had negative biopsy results and need further evaluation. Two of these 5 patients had primary diagnoses of HD, that may affect the marrow focally. Bilateral biopsy is essential in these suspected cases.

Although it may be criticised that the biopsy sites and imaging sites were different from each other, high concordance of the results between biopsy and MRI suggest that in the group of patients with inhomogenous involvement unilateral blind biopsy of the iliac crest, which is routinely used in the staging of malignant lymphoma, but is less sensitive than MR imaging, with which more than one region can be evaluated.

In this study, it might be more feasible in selected cases with discordant results to perform bilateral biopsy and even MRI guided biopsy to confirm our results. With the

available data, we can conclude that MRI of lumbar spine is a non-invasive way of demonstrating bone marrow infiltration, which has to be used as an adjunct to unilateral blind bone marrow biopsy.

## References

1. Shipp MA, Mauch PM, Harris NL: Non-Hodgkin's Lymphomas. In: DeVita VT Jr, Hellman S, Rosenberg SA, eds. Cancer, Principles and Practice of Oncology. 5<sup>th</sup> ed. Lippincott-Raven, Philadelphia, 1997:2165-2220.
2. DeVita VT Jr, Mauch PM, Harris NL: Hodgkin's Disease. In: DeVita VT Jr, Hellman S, Rosenberg SA, eds. Cancer, Principles and Practice of Oncology. 5<sup>th</sup> ed. Lippincott-Raven, Philadelphia, 1997:2242-2283.
3. Bartl R, Frisch B, Burkhardt R, et al: Lymphoproliferations in the bone marrow: identification and evolution, classification and staging. *J Clin Pathol* 37:233-254, 1984.
4. Burkhardt R, Frisch B, Bartl R: Bone marrow biopsy in hematologic disorders. *J Clin Pathol* 8: 257-284, 1982.
5. Westerman MP: Bone marrow needle biopsy: an evaluation and critique. *Semin Hematol* 18:293-300, 1981.
6. Collier BS, Chabner BA, Gralnick HR: Frequencies and patterns of bone marrow involvement in non-Hodgkin lymphoma: observations on the value of bilateral biopsies. *Am J Pathol* 3:105-119, 1977.
7. Brunning RD, Bloomfield CD, McKenna RW, et al: Bilateral trephine bone marrow biopsies in lymphoma and other neoplastic diseases. *Ann Intern Med* 82:365-366, 1975.
8. Rosenberg SA: Hodgkin's disease of the bone marrow. *Cancer Res* 31:1733-1736, 1971.
9. Datz FL, Taylor A: The clinical use of radionuclide bone marrow imaging. *Semin Nucl Med* 15:239-259, 1985.
10. McAfee JG, Subramanian G, Aburano T, et al: A new formulation of Tc-99m minimicroaggregated albumin for marrow imaging: comparison with other colloids, In-111 and Fe-59. *J Nucl Med* 23:21-28, 1982.
11. Naughton MJ, Hess JL, Zutter MM, et al: Bone marrow staging in patients with non-Hodgkin's lymphoma. Is flow cytometry a useful test? *Cancer* 82:1154-1159, 1998.
12. Smith SR, Roberts N, Percy DF, et al: Detection of bone marrow abnormalities in patients with Hodgkin's disease by T1 mapping of MR images of lumbar vertebral bone marrow. *Br J Cancer* 65:246-251, 1992.
13. Linden A, Zankovich R, Theissen P, et al: Schicha H. Malignant lymphoma: Bone marrow imaging versus biopsy. *Radiology* 173:335-339, 1989.
14. Daffner RH, Lupetin AR, Dash N, et al: MRI in the detection of malignant infiltration of bone marrow. *Amer J Roentgenol* 6;146:353-358, 1986.
15. Murphy WA, Totty WG: Musculoskeletal magnetic resonance imaging. *Magn Reson Ann*:1-35, 1986.
16. Vogler JB, Murphy WA: Bone marrow imaging. *Radiology* 168:679-693, 1988.
17. Steiner RM, Mitchell DG, Rao VM, et al: Magnetic resonance imaging of bone marrow, diagnostic value in diffuse hematologic disorders. *Magnet. Reson. Quart.* 6:17, 1990.
18. Moore SG, Gooding CA, Brasch RC, et al: Bone marrow in children with acute lymphocytic leukemia: MR relaxation times. *Radiology* 160:237-240, 1986.
19. Richards MA, Webb JAW, Jewell SE, et al: Low field strength magnetic resonance imaging of bone marrow in patients with malignant lymphoma. *Br J Cancer* 57:412, 1988.

20. *Non-Hodgkin's lymphoma pathologic classification project*. National Cancer Institute sponsored study of classifications of non-Hodgkin's lymphomas: summary and description of a Working Formulation for clinical usage. *Cancer* 49:2112, 1982.
21. *Kapadia SB, Krause JR*: Hodgkin's disease. In: Krause JR, ed. *Bone marrow biopsy*, Churchill Livingstone, Edinburgh, 145-155 1981.
22. *Williams WJ, Nelson DA*: Examination of the marrow. In: Williams WJ, Beutler E, Erslev AJ, Lichtman MA, eds. *Hematology*, 4<sup>th</sup> edition, McGraw Hill, USA, 24-31, 1991.
23. *Fineberg S, Marsh E, Alfonso F, et al*: Immunophenotypic evaluation of the bone marrow in non-Hodgkin's lymphoma. *Hum Pathol* 24:636-642, 1993.
24. *Christy M*: Active bone marrow distribution as a function of age in humans. *Phys Med Biol* 26:389-400, 1981.
25. *Trubowitz S, Davis S*: The bone marrow matrix. In: Trubowitz S, Davis S, eds. *The human marrow anatomy, physiology and pathophysiology*. Vol 1. Boca raton: CRC, 43-76, 1982.
26. *Brateman L*. Chemical shift imaging: a review. *Amer J Roentgenol* 146:971-981, 1986.
27. *McKinstry CS, Steiner RE, Young AT, et al*: Bone marrow in leukemia and aplastic anemia: MR imaging before, during and after treatment. *Radiology* 162:701-707, 1987.
28. *Rahmouni A, Divine M, Mathieu D, et al*: MR appearance of multiple myeloma of the spine before and after treatment. *Amer J Roentgenol* 160:1053-1057, 1993.
29. *Moulopoulos LA, Varma DGK, Dimopoulos MA, et al*: Multiple myeloma: spinal mr imaging in patients with untreated newly diagnosed disease. *Radiology* 185:833-840, 1992.
30. *Shields AF, Porter BA, Churchley S, et al*: The detection of bone marrow involvement by lymphoma using magnetic resonance imaging. *J Clin Oncol* 5:225-230, 1987.
31. *Rosen BR, Fleming DM, Kushner DC, et al*: Hematologic bone marrow disorders: Quantitative chemical shift mr imaging. *Radiology* 169:799-804, 1988.
32. *Sugimura K, Yamasaki K, Kitagaki H, et al*: Bone marrow diseases of the spine: Differentiaiton with T1 and T2 relaxation times in MR imaging. *Radiology* 165:541-544, 1987.
33. *Simon JH, Szumowski J*: Proton (fat/water) chemical shift imaging in medical magnetic resonance imaging: current status. *Invest Radiol* 27:865-874, 1992.
34. *Mirowitz SA, Apicella P, Reinus WR, et al*: MR imaging of bone marrow lesions: Relative conspicuousness on T1-weighted, fat suppressed T2-weighted and STIR images. *Amer J Roentgenol* 162:215-221, 1994.
35. *Staller DW, Porter BA, Steinkirchner TM*: Marrow Imaging In: Staller DW. *Magnetic Resonance Imaging in Orthopaedics and Sports Medicine*. J.B. Lippincott Company, Philadelphia, 1996, 2<sup>nd</sup> ed.