

ARTICLE

p53 Immunohistochemical Expression of Egyptian Cervical Carcinoma

Howayda ABD EL ALL^{1*}, Annie RYE,² Pierre DUVILLARD³

¹Department of Pathology, Faculty of Medicine, Suez Canal University, Egypt;

²Department of Statistics and ³Department of Pathology, Institute Gustave Roussy, Villejuif, France

Data concerning the expression of p53 in cervical carcinoma, one of the leading cause of death in developing countries, are still confusing. This study was designed to identify p53 in Egyptian cervical carcinoma in an attempt to evaluate its prognostic significance. Eleven chronic cervicitis and 38 invasive carcinoma (31 squamous cell carcinoma (sqcc) and 7 adenocarcinoma, ranging from stage IB to IVB), were stained with the monoclonal antibody anti p53, DO7, using the microwave for antigen retrieval. No immunoreactivity was detected in chronic cervicitis, while nuclear p53 reactivity was detected in all carcinoma and in squamous intraepithelial lesions (SIL) overlying 8 sqcc. P53 immunohistochemical (IHC) expression was more

pronounced in early clinical stages ($p=0.007$) and in adenocarcinoma compared to sqcc ($p=0.015$). A positive correlation was present between p53 and heat shock protein 70 (hsp70) expressions ($p=0.005$). No correlation could be found between p53 expression and tumor infiltrating lymphocytes, the presence or absence of either schistosomiasis or HPV infections. It can be concluded, that in the Egyptian population, p53 immunoreactivity appears to be an early event in cervical neoplasm, and seems to play an important role together with other cell regulatory proteins in the process of carcinogenesis, which could be different between sqcc and adenocarcinoma. (Pathology Oncology Research Vol 5, No 4, 280–284, 1999)

Keywords: cervical carcinoma, p53, FIGO staging

Introduction

Cervical carcinoma is the second leading cause of death in women worldwide.³⁰ In Egypt, cervical carcinoma represent 59,58% of female genital tract malignancies according to the statistics of the National Cancer Institute of Egypt.²⁵ Many factors are implicated in the process of cervical carcinogenesis. In the western population, there is evidence that human papilloma virus infection (HPV) especially 16 and 18 subtypes are involved in the development of cervical carcinoma.⁴¹ Data concerning HPV

infection in Egypt are lacking and information regarding the possible role of schistosomiasis in the process of cervical carcinogenesis are debatable.^{26,40}

The suppressor gene p53 plays a pivotal role in protection against the development of cancer. Its wild type monitor the integrity of the genome.²¹ The mechanism of p53 activation in response to DNA damage depends on DNA-protein kinase.³⁷ Studies on the value of p53 in cervical carcinoma are controversial. Some studies showed that p53 protein accumulation may be an early event in carcinogenesis,¹⁹ while for others, p53 overexpression or mutation did not seem to play a significant role in cervical carcinogenesis.^{24,27} The mechanism of inactivation or loss of the wild type in the development of cervical carcinoma, has been attributed to either mutation within the genome or the presence of virally encoded p53 binding protein.²¹ Mutant p53 could form an oligomeric complex with wild type preventing the latter from functioning, or alternatively mutant p53 could gain a new oncogenic function that overcomes the negative regulation by small quantities of

Received: May 2, 1998; *accepted:* February 10, 1999

Correspondence: Howayda ABD EL ALL, M.D., Department of Pathology, Faculty of Medicine, Suez Canal University, Ismailia, Egypt; Tel: + (202) 274-32-31; Fax: + (202) 274-36-70; e-mail:howayda@intouch.com

Abbreviations: sqcc: squamous cell carcinoma; IHC: immunohistochemistry; SIL: squamous intraepithelial lesion; HPV: human papilloma virus infection

wild type.⁷ Based upon recent advances, several therapeutic strategies had been envisioned concerning the structure and function of the p53 protein, its interaction with cellular and viral proteins and its roles in repairing DNA, regulating cell division and promoting apoptosis and other approaches had focused on restoring p53 function in human tumors.^{4,18}

We performed this work in order to study the significance of IHC expression of p53 in invasive cervical carcinoma in the Egyptian population and to correlate this expression with the FIGO clinical staging, the histopathologic type and grade, the presence or absence of HPV and schistosomiasis.

Materials and Methods

Patients

Samples were available from 38 untreated patients with invasive cervical carcinoma, 23 by punch biopsy and 15 by radical hysterectomy. All patients were included in two previous studies.^{1,2} As the treatment modality for stages IB and IIA is different from stages IIB, III and IV,⁹ and for statistical purposes, we designated the former as early clinical stages and the later as late stages. The control tissues were cervixes diagnosed as chronic non specific cervicitis. Tissues from all cases were fixed in 10% neutral buffered formalin and processed through to paraffin. Fixation was done at room temperature for a maximum period of 36 hours.

Immunohistochemistry

For immunostaining, 5 µm thick sections were dewaxed in xylene over night, dehydrated in decreasing concentrations of alcohol ending in phosphate buffer saline (PBS). The step of deparaffinization was critical, since slides immersion in xylene for 15 to 30 minutes were negative for staining and few cells were stained by immersion for 60 minutes. The microwave oven heating method was used for antigen retrieval. Sections were irradiated at 750w for 15 minutes in citrate buffer (pH 6.0) (3 x 5 minutes) cycles with 1 minute interval between cycles to check out the fluid level. Slides were left to cool for 15 minutes, rinsed in distilled water twice and finally in PBS. The staining steps was performed according to the manual supplied with the labeled streptavidin biotin kit (DAKO) and the mouse monoclonal antibody DO-7 (DAKO) that react with the wild and mutant type p53 at a dilution of 1:50. The duration of incubation performed at room temperature was 90 minutes. Positive staining was visualized with 3,3 diaminobenzidine tetrachloride (DAB). For counterstaining methyl green was used. Only nuclear staining was considered positive. Both the number or percentage of positive cells and the intensity of staining were assessed. The

staining intensity was graded as follows: absent (-), mild (+), moderate (++) , severe (+++). The percentage of positive cells was assessed in a semi-quantitative manner in 10 high power fields as follows: 1. 1-5% positive cells, 2. 6-25%, 3. 26-50%, 4. 51-75% and 5. >75%. The p53 score was the sum of the intensity and percentage of positive. Negative controls were parallel sections treated as above with omission of the primary antibodies.

In situ hybridization

This was previously done and detailed.¹ Briefly, the OmniProbe and the DAKO in situ detection system for biotinylated probes were used for initial screening of all the tumors (DAKO). OmniProbe, is a wide spectrum HPV biotinylated probe for which the targets are the genomic DNAs of HPV types 6, 11, 16, 18, 30, 33, 35, 45, 51 and 52. Positive staining was present in 5 cases for which further subtyping with the probes directed against HPV 6/11, 16 and 18 (Kreatech) were performed according to the supplied manual with the Kreatech In Situ Hybridization Detection Kit. Negative controls were non-specific DNA probes supplied with the kits. Tissue specimens, condylo-ma and SIL known for their positivity with the probes were used as positive controls.

Statistical analysis

The correlation between the p53 and the different parameters was performed using the Chi square test. The 95% confidence interval for the rho values were calculated.

Results

There was no detectable p53 protein in non neoplastic tissues. All carcinomas were stained with the p53 DO7, with 7/38 (18%) having the maximum score 8 (*Figure 1A*). The staining was only nuclear either as fine or as coarse granular dots. The expression was greater in the peripheral cells of tumor islands in sqcc especially in the large cell keratinized subtype. There was marked heterogeneity between and within tumors. There being within the same section, islands of cells that were virtually negative, others having 1 to 5% of reactive cells and others with more than 75% positive cells. This heterogeneity was marked in adenocarcinoma (*Figure 1B*). In low grade SIL, the nuclear staining was confined to the basal layer until reaching the superficial one in high grade SIL. Tumor cells beneath these SIL had the same staining intensity but their number were increased. P53 immunoreactivity was detected in HPV positive and negative cases without significant differences between both groups. Similarly, p53 was detected in tumors with and without bilharziasis (*Table 1*). Metastatic cancerous cells infiltrating lymph nodes

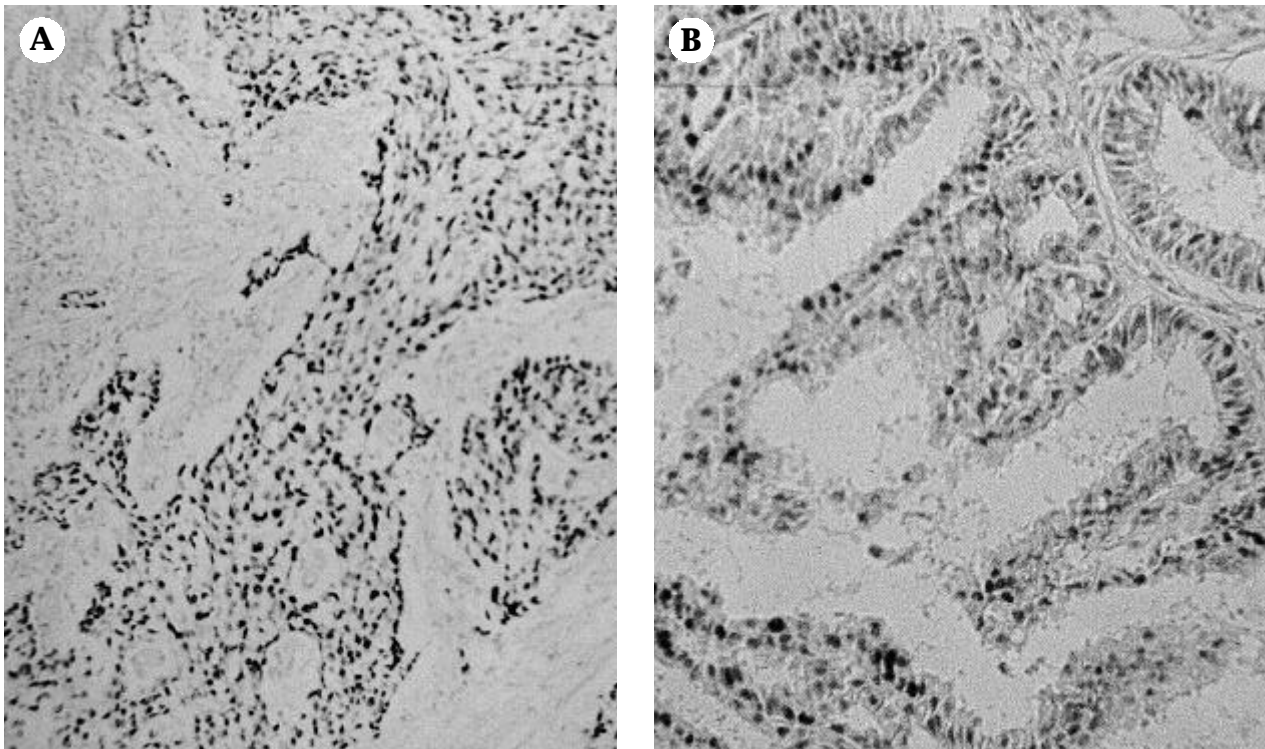


Figure 1. (A) Nuclear expression of p53 in islands of malignant large cell non keratinized sqcc. All the cells are stained (x100), and (B) Nuclear expression of p53 in malignant endocervical carcinoma. Note the staining heterogeneity x250. P53DO7- methyl green counterstaining.

showed the same staining intensity with the anti p53 as their primary tumors. P53 was more expressed in early clinical stages ($p=0.0007$) and in adenocarcinoma compared to sqcc ($p=0.015$) (Table 2 and Figure 2). A positive correlation was noted between p53 and hsp70 previously studied (2) ($p=0.005$). No correlation was present with the other variable.

Discussion

The results of IHC of p53 in cervical carcinoma have been somewhat confusing. p53 immunoreactivity was detected in normal and inflammatory lesions of the cervix, explained as a result of overexpression or stabilization of the wild type as noted by Bosari et al,⁵ or as an effect of the microwave oven heating in the absence of mutations.^{16,20} In the present study search for p53 using the microwave oven heating, showed lack of expression of the protein in chronic cervicitis, an observation in agreement with other studies.^{13,33} However in the latter study, p53 was not expressed in condyloma, dysplastic tissues and carcinoma in situ while in the present work p53 immunoreactivity started in SIL. The expression began to be seen in few cells in the basal layer of low grade SIL and increased to parallel the extension of neoplastic cells in high grade SIL and carcinoma in situ and was more extensive in inva-

sive lesions. The same observation was documented in previous studies.^{5,11,16,19} This may suggest that abnormal p53 expression participate alone or with other factors in the transformation of non neoplastic epithelium to SIL and latter on in the development of invasive cervical lesions. A similar finding in colorectal tumorigenesis was detected, where p53 alterations take place at the transition from adenoma to carcinoma.^{29,35}

Looking for the association of p53 with staging, studies are controversial. A significant pronounced expression of p53 in early clinical stages, has been reported in the work of Lakshmi et al.¹⁹ Most of the studies showed a lack of asso-

Table 1. Expression of p53 in bilharziasis and HPV associated cervical carcinoma.

%p53	Bilharziasis		HPV		
	Ova*	TTT**	16	18	Omniprobe
1-5	3	5	1		
6-25		1		2	
26-50	2	1			1
51-75					1
>75	2	1			

* ova in the neoplastic tissue

** treatment for urinary bilharziasis

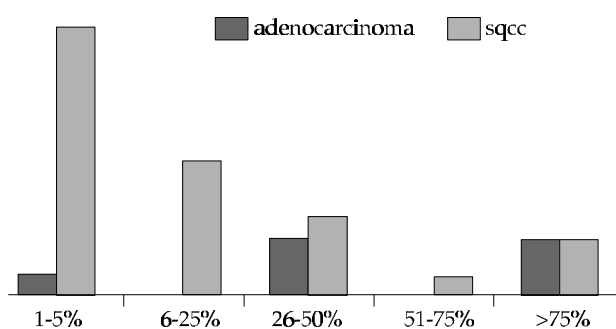


Figure 2. p53 IHC expression in adenocarcinoma and squamous cell carcinoma ($p = 0.0015$)

ciation between p53 IHC expression and staging. Oka et al²⁸ noted that p53 CM1 expression in 49/119 stage III sqcc cases was not a predictive factor for the prognosis in cervical carcinoma. Helland et al¹¹ in 50/92 stage I-IV cases failed to find significant association between NCL-CM1 p53 protein expression and the clinical stage. Kainz et al¹⁷ using the monoclonal antibody BP53-12 on 109 sqcc stage IB-IIIB failed to show any correlation. Using the same antibody in this study p53 DO7, Hunt et al did not find relation between p53 and staging.¹⁴ What is the significance of the early expression found in our study on our patients? We have noted in 2 cases of adenocarcinoma stage IIA, that p53 overexpression was associated with nodal metastasis and recurrence. Unfortunately, more than half of our patients were lost for follow up and we cannot find the significance of such expression on the clinical outcome of the patients. A long term study is needed to clarify this point.

We have previously shown an association between schistosomiasis infection and cervical carcinoma ($p=0.005$) and advanced clinical staging ($p=0.03$).¹ The mechanism underlying the carcinogenic effect of bilharziasis has been attributed to several mechanisms, one of them was a possible involvement of loci on chromosome 11 in controlling the level of chromosomal breakage caused by oxidative damage of the inflammatory cells.³⁴ We expected to find a relationship between schistosomiasis and p53 as we have

found association between p53 and early clinical staging, but this was not the case.

Similarly, we failed to find association between p53 and HPV. Overexpression of p53 in tissues has generally been assumed to reflect p53 mutations in HPV negative cervical carcinoma, since in HPV positive cases, the wild type p53 complex with E6 of HPV 16 or 18, is degraded and cannot be detected by IHC.^{6,12,22} Did the expression of p53 in 33/38 HPV negative cases reflected mutation? We believe so, as we found an increased expression of c-myc and hsp70 in the same cases,² and we found a direct correlation between IHC nuclear expression of hsp70 and p53 ($p=0.005$). In addition, examination of serial sections stained for hsp70 and p53 revealed co-localization of both in the nucleus of the same cell. Early studies showed interactions between mutant p53 protein and hsp70.^{3,31} Recently, mutations in the p53 protein has been shown to alter the tertiary structure of the central DNA binding domain, thus exposing high affinity hsp70 binding sites that are cryptic in the wild type molecule, therefore allowing the interaction between both mutant and hsp70.¹⁰ This finding in cervical carcinoma contradicted studies on breast carcinoma where only part of the p53 pool was found to be bound to hsp70,¹⁵ and that the nuclear accumulation of p53 was not associated with cytoplasmic or nuclear hsp70.⁸

Regarding the over-expression of p53 in the HPV positive cervical carcinoma cases, we think that this might be due to non mutational stabilization of the p53 protein. Wynford-Thomas^{38,39} suggested that the IHC detection of p53 may requires not only mutation of the gene but some additional secondary unknown mechanism of non mutational stability conferred by the neoplastic cells and that not all p53 detected by IHC should be considered mutated. Does this stabilization was conferred by the co-association of p53 with other molecules such as hsp70 and/or c-myc? A point needing further evaluation on molecular basis.

The finding of a pronounced p53 expression in adenocarcinoma compared to sqcc confirm the biologic difference between the two subtypes.³² The expression of p53 in cervical adenocarcinoma in the literature was less fortunate than its squamous counterpart. McCluggage and colleagues found the expression in 23/33 cases of adenocarcinoma, 2/10 adenocarcinoma in situ, and concerning the non neoplastic tissue, in 2/10 tubo-endometrial metaplasia, 1/10 microglandular hyperplasia, and 1/17 normal endocervical tissues.²³ In another study, on 25 cervical adenocarcinoma and 7 adenosquamous carcinomas, Uchiyama et al³⁶ showed that HPV-negative or p53-positive adenocarcinoma may be a biologically distinct subset with a poorer prognosis.

Table 2. Relation between p53 expression and FIGO staging

%p53	FIGO staging					
	IB	IIA	IIB	IIIA	IIIB	IVA
1-5		2	3	1	8	2
6-25	1		5		1	
26-50	4	1	1	1		
51-75	1					
>75	1	1	1	2	1	1
95% CI	2.46-3.82	0.59-4.42	1.29-2.71	1.59-5.71	0.70-2.30	0.00-7.00

$p=0.0007$

Other studies failed to demonstrate staining in 13 adenocarcinoma examined.²⁴

In conclusion, we have documented p53 immunoreactivity in all cervical carcinoma either HPV positive or negative and in cases with or without schistosomiasis. This expression was significantly associated with early clinical stages and adenocarcinoma and appears to be related to p53 mutation.

References

- ¹Abd El All H, Prade M, ²Khatib T, et al: Immunological study of NK cells in cervical carcinoma. Ph.D. Thesis, Faculty of Medicine, Suez Canal University, Ismailia, Egypt, 1992.
- ²Abd El All H, Rey A, Duvillard P: Expression of heat shock protein 70 and c-myc in cervical carcinoma. *Anticancer Res* 18:1533-1536, 1998.
- ³Agoff S, Hou J, Linzer DI, et al: Regulation of the human hsp70 promoter by p53. *Science* 259:5091 84-87, 1993.
- ⁴Beaudry GA, Bertelsen AH, Sherman MF: Therapeutic targeting of the p53 tumor suppressor gene. *Curr Opin Biotechnol* 7:592-600, 1996.
- ⁵Bosari S, Roncalli M, Viale G, et al: p53 immunoreactivity in inflammatory and neoplastic diseases of the uterine cervix. *J Pathol* 169:425-430, 1993.
- ⁶Crook T, Wrede D, Vousden HK: p53 point mutation in HPV negative human cervical carcinoma cell lines. *Oncogene* 6:873-875, 1991.
- ⁷Dittmer D, Pati S, Zambetti G, et al: Gain of function mutations in p53. *Nat Genet* 4:42-46, 1993.
- ⁸Elledge RM, Clark GM, Fuqua SA, et al: p53 protein accumulation detected by five different antibodies: relationship to prognosis and heat shock protein 70 in breast cancer. *Cancer Res* 54:3752-3757, 1994.
- ⁹Farias-Eisner RP, Walker DL, Berek JS: *Gynecol Cancers*. In: *Manuel of Clinical Oncology*. Ed Casciato DA and Lowitz BB. 3rd edition. Little, Brown Co, Boston- Massachusetts. pp 200-227, 1995.
- ¹⁰Fourie AM, Hupp TR, Lane DP, et al: HSP70 binding sites in the tumor suppressor protein p53. *J Biol Chem* 272:19471-19479, 1997.
- ¹¹Helland A, Holm R, Kristensen G, et al: Genetic alterations of the TP53 gene, p53 protein expression and HPV infection in primary cervical carcinomas. *J Pathol* 171:105-114, 1993.
- ¹²Helland A, Karlsen F, Due EU, et al: Mutations in the TP53 gene and protein expression of p53, MDM 2 and p21/WAF-1 in primary cervical carcinomas with no or low human papillomavirus load. *Br J Cancer* 78:69-72, 1998.
- ¹³Holm R, Skomedal H, Helland A, et al: Immunohistochemical analysis of p53 protein overexpression in normal, premalignant, and malignant tissues of the cervix uteri. *J Pathol* 169:21-26, 1993.
- ¹⁴Hunt CR, Hale RJ, Buckley CH et al: p53 expression in carcinoma of the cervix. *J Clin Pathol* 49:971-974, 1996.
- ¹⁵Iwaya K, Tsuda H, Fujita S, et al: Natural state of mutant p53 protein and heat shock protein 70 in breast cancer tissues. *Lab Invest* 72:707-714, 1995.
- ¹⁶Jeffers MD, Richmond J, Farquharson M, et al: p53 immunoreactivity in cervical intraepithelial neoplasia and non-neoplastic cervical squamous epithelium. *J Clin Pathol* 47:1073-1076, 1994.
- ¹⁷Kainz C, Kohlberger P, Gitsch G, et al: Mutant p53 in patients with invasive cervical cancer stages IB to IIB. *Gynecol Oncol* 57:212-214, 1995.
- ¹⁸Kubbutat MH, Vousden KH: Keeping an old friend under control: regulation of p53 stability. *Mol Med Today* 4:250-256, 1998.
- ¹⁹Lakshmi S, Nair MB, Jayaprakash PG, et al: p53 protein and tumorigenesis in the uterine cervix. *Gen Diagn Pathol* 142:281-287, 1997.
- ²⁰Lambkin HA, Mothersill CM, Kelehan P: Variations in immunohistochemical detection of p53 protein overexpression in cervical carcinomas with different antibodies and methods of detection. *J Pathol* 172:13-18, 1994.
- ²¹Lane DP: P53, guardian of the genome. *Nature* 358:15-16, 1992.
- ²²Levine AJ, Momand J, Finlay CA: P53 tumor suppressor gene. *Nature* 351:453-451, 1991.
- ²³McCluggage G, McBride H, Maxwell P, et al: Immunohistochemical detection of p53 and bcl-2 proteins in neoplastic and non-neoplastic endocervical glandular lesions. *Int J Gynecol Pathol* 16:22-27, 1997.
- ²⁴Mittal KR, Lin O, Chan W et al: Cervical squamous dysplasias and carcinomas with immunodetectable p53 frequently contain HPV. *Gynecol Oncol* 58:289-294, 1995.
- ²⁵Mokhtar N: *Cancer Pathology Registry 1985-1989*. Ed Department of Pathology NCI, 1991.
- ²⁶Moubayed P, Ziehe A, Peters J, et al: Carcinoma of the uterine cervix associated with schistosomiasis and induced by human papillomaviruses. *Int J Gynaecol Obstet* 49:175-179, 1995.
- ²⁷Ngan HY, Tsao SW, Liu SS, et al: Abnormal expression and mutation of p53 in cervical cancer-a study at protein, RNA and DNA levels. *Genitourin Med* 73:54-58, 1997.
- ²⁸Oka K, Nakano T, Arai T: p53CM1 expression is not associated with prognosis in uterine cervical carcinoma. *Cancer* 72:160-164, 1993.
- ²⁹Pignatelli M, Stamp GW, Kafiri G, et al: Over-expression of p53 nuclear oncoprotein in colorectal adenomas. *Int J Cancer* 50:683-688, 1992.
- ³⁰Pillai MR, Halabi S, McKalip A, et al: The presence of human papillomavirus-16/-18 E6, p53, and Bcl-2 protein in cervicovaginal smears from patients with invasive cervical cancer. *Cancer Epidemiol Biomarkers Prev* 5:329-335, 1996.
- ³¹Pinhasi-Kimhi O, Michalovitz D, Ben-Zeev A, et al: Specific interaction between the p53 cellular tumour antigen and major heat shock proteins. *Nature* 320:182-184, 1986.
- ³²Quinn MA: Adenocarcinoma of the cervix- Are there arguments for a different treatment policy? *Current Opinion in Obst Gynecol* 9:21-24, 1997.
- ³³Raju GC, Teh M and Wee A: An immunohistochemical study of p53 protein in cervical intraepithelial neoplasia and squamous cell carcinoma. *Pathology* 28:17-19, 1996.
- ³⁴Rosin MP, Anwar WA, Ward AJ: Inflammation, chromosomal instability, and cancer: the schistosomiasis model. *Cancer Res* 54:1929s-1933s, 1994.
- ³⁵Shan L, Nakamura Y, Zhang Z, et al: Overexpression of p53 protein correlates with a high risk of malignant transformation of adenomas in patients with multiple colorectal adenomas. *Pathol Int* 48:281-286, 1998.
- ³⁶Uchiyama M, Iwasaka T, Matsuo N, et al: Correlation between human papillomavirus positivity and p53 gene overexpression in adenocarcinoma of the uterine cervix. *Gynecol Oncol* 65:23-29, 1997.
- ³⁷Woo RA, McLure KG, Lees-Miller SP, et al: DNA-dependent protein kinase acts upstream of p53 in response to DNA damage. *Nature* 394:700-704, 1998.
- ³⁸Wynford-Thomas D: Oncogenes and anti-oncogenes; the molecular basis of tumour behaviour. *J Pathol* 165:187-201, 1991.
- ³⁹Wynford-Thomas D: P53 in tumour pathology: can we trust immunocytochemistry? *J Pathol* 166:329-330, 1992.
- ⁴⁰Youssef AF, Fayad MM and Shafeek M: Bilharziasis of the uterine cervix. *J Obstet Gynaecol Brit Commonw* 77:847-851, 1970.
- ⁴¹Zur Hausen H: Papilloma viruses in anogenital cancer as a model to understand the role of viruses in human cancers. *Cancer Res* 49:4677-851, 1989.