

ARTICLE

Tenascin Expression in Primary and Recurrent Breast Carcinomas and the Effect of Tenascin on Breast Tumor Cell Cultures

Anna-Mária TÖKÉS,¹ Sándor PAKU,² Sára TÓTH,³ Edina PAÁL,¹ Janina KULKA,¹ József TÓTH,⁴
András TELEKES⁴

¹2nd Department of Pathology, ²1st Department of Pathology and Experimental Cancer Research,

³Department of Genetics, Cell and Immunobiology, Faculty of Medicine, Semmelweis University,

⁴National Institute of Oncology, Budapest, Hungary

Tenascin is generally classified as an anti-adhesive protein. Many cells do not adhere to tenascin or if they adhere they do not spread. In this study we analysed the stromal expression of tenascin-C in primary, second primary and recurrent breast carcinomas and the ability of tenascin-C to stimulate the focal adhesion plaques in MDA-MB-435 breast carcinoma cell line. To assess the tenascin-C expression formalin-fixed, paraffin-embedded specimens of 20 specially selected breast carcinomas and their recurrences (14) or a second primary breast cancer of the same patient (6) were examined with immunohistochemical methods. We also studied the effect of tenascin-C on focal adhesion plaques added to MDA-MB-435 breast carcinoma cell line.

Keywords: tenascin, breast cancer, cell cultures, focal adhesion plaques

During a median 2,9-year patient follow up 14 local recurrences and 6-second primary breast carcinomas developed in the 20 patients. In 3 cases a second recurrence occurred. The presence of tenascin in tumor cells, in the proliferating and some normal ducts, near to the tumor cell nests, in the stroma and in ductal carcinoma in situ component of the invasive carcinoma may suggest the role of tenascin played in tumor cell migration. Soluble tenascin added to the cell culture had minimal or no effect on focal adhesion plaques. Tenascin only seems not to be of prognostic value in predicting the local recurrence of breast cancer. (Pathology Oncology Research Vol 6, No 3, 202–209, 2000)

Introduction

Activation and enhanced migration of cells in the embryonic period, during wound healing and progression of malignant neoplasia are associated with distinct patterns of extracellular matrix (ECM) composition compared to adult and normal status.^{7,10} One of the ECM proteins that appears in variable patterns during development and tumor progression is tenascin-C (TN) a large disulfide-bonded glycoprotein. The predominant form of TN observed by electron microscopy is a six-armed oligomer. Human TN shows a single prominent band at 320 kDa and minor

bands of 220 and 230 kDa on reducing polyacrylamide gel electrophoresis.³⁰

What is the secret of TN? A wide range of studies aiming to clarify the role of this ECM glycoprotein in cellular functions has been published. TN is expressed in association with mesenchymal/epithelial interactions during development,^{11,32} in the neovasculature³³ and the stroma of some tumors.^{1,22} In breast, TN was initially observed selectively in the condensed stroma near budding epithelial cells of developing mammary ducts and also in the stroma of malignant tumors.²² The most consistent function of TN seems to be that it decreases cell adhesion, or it has been suggested that TN could promote cancer cell invasion and metastasis.^{26,36} Experiments with substrates coated with TN and fibronectin (FN) have shown that TN inhibits the attachment of fibroblasts on FN or laminin.⁶ A weak or transient attachment would be expected when a cell expresses

Received: Jan 25, 2000; *accepted:* June 5, 2000;

Correspondence: Anna-Mária TÖKÉS, 2nd Department of Pathology, Semmelweis University, Üllői út 93. Budapest 1091 Hungary, Tel.: 36-1-215-7300, Fax.: 36-1-215-6921/3402, e-mail: ta@korb2.sote.hu

Table 1. Clinicopathological data of the tumors

Case	Surgery* (year)	Age/ first diag.	Diagnosis/ 1.surgery	Gr.	NS.	Tumor size	Diagnosis/ 2.surgery	Gr.	NS.	Tumor size	Diagnosis/ 3. surgery	Gr.	NS.	Tumor size
1	1996	49	Invasive lobular carcinoma	I	4/0	40 mm	Invasive papillary carcinoma	II	6/0	5 mm				
2	1995	60	Invasive ductal carcinoma (IDC)	II	5/3	14 mm	Post-irradiation fibrosis + IDC	II	-	15 mm				
3	1997	50	IDC+ductal Papillomatosis	II	6/1	23 mm	IDC+ductal carcinoma in situ (DCIS)	III	-	25 mm				
4	1994	47	IDC+ DCIS	II	7/4	17 mm	Tubulo-lobular carcinoma	I	3/0	15 mm	Fibrocystic breast			
5	1995	53	IDC	II	8/2	35 mm	Recurrent IDC	II	-	-	Recurrent IDC			
6	1994	61	IDC	II	-	-	Recurrent IDC	I	-	-				
7	1996	65	IDC+DCIS	II	10/0	20 mm	Recurrent IDC+DCIS	II	-	5 mm				
8	1995	62	IDC+DCIS	II	0	27×18 mm	Recurrent IDC	II	-	5 mm				
9	1997	61	Paget's disease + IDC	-	-	-	IDC	II	15/0	20×10 mm				
10	1996	52	IDC	III	15/15	30 mm	Recurrent IDC	II	-	35 mm				
11	1997	86	IDC	II	-	7 mm	Recurrent IDC	I	-	12 mm				
12	1996	37	IDC	II	-	12 mm	Recurrent IDC	II	-	25 mm				
13	1997	75	IDC	I	-	13 mm	Recurrent IDC	II	-	7 mm				
14	1993	76	IDC+ mucinous carcinoma	II	-	18 mm	Recurrent IDC	II	-	25 mm				
15	1997	55	IDC	II	-	10-12 mm	Recurrent IDC	II	-	30 mm				
16	1994	53	IDC+ medullary carcinoma	II	-	-	Recurrent IDC	III	-	14×12 mm	Recurrent IDC	III	-	30 mm
17	1995	76	IDC	II	-	-	Recurrent IDC	III	-	-	Recurrent IDC	III	3/3	10 mm
18	1993	62	IDC	II	0	30 mm	Recurrent IDC	II	-	-				
19	1988	44	IDC	III	21/12	20 mm	Recurrent IDC	II	-	-				
20	1994	75	Neuroendocrine carcinoma	I	0	-	IDC	II	-	11 mm	Recurrent IDC	I	-	10×15 mm
	1996													
	1998													

Gr-grade; NS-nodal status; *Year of 1. or 2. or 3. surgery

receptors for the substrate molecule. In vitro TN binds to immobilised FN⁸ and to cell surface proteoglycans.⁴ Other data provide evidence of adhesive domains of TN that interact with chondroitin sulphate or with RGD (Arg-Gly-Asp) -sensitive integrin.¹ Several authors have presented a functional antagonism between TN and FN.^{14,17,21,37} Soluble TN inhibits the adhesion of human mammary carcinoma cells⁷ to FN-coated plastic and to collagen gels. Other authors reported no effect of soluble TN on initial adhesion of fibroblast to FN.³² Some data demonstrate that TN, thrombospondin and SPARC act as soluble ligands, being able to provoke loss of focal adhesion in well-spread endothelial cells.²³ Cell culture experiments suggest that TN promote cell growth by augmenting the mitogenic effect of fibroblast growth factor and that this is a prerequisite for epidermal growth factor induced proliferation.^{26,36} These various approaches have been taken to elucidate the roles that TN might play in regulatory cell behaviour, detachment and loss of intercellular contacts, inhibition of cell migration and spreading.

The aim of this work was to assess the relationship between the expression of TN in breast tumors and some biological variables and to compare its usefulness in predicting local recurrences.

Closer to understand better the role of TN played in breast cancers, the ability of TN to stimulate the focal adhesion in MDA-MB-435 breast carcinoma cell line was also analysed.

Materials and Methods

Surgical breast cancer specimens were examined biopsy from 20 female patients (age range 37–86 years). The mean follow-up period of the patients was 2,9 years, ranging from 1 to 10 years. During this period 14 patients of 20 from local recurrences and 3 of them had a second recurrence; 6 developed a second primary breast carcinoma. Both the recurrences and the second primary tumors were analysed.

Three µm thick sections were cut from formalin fixed (4%, neutrally buffered), paraffin embedded samples. Tubule formation, nuclear morphology and mitotic rate were evaluated and scored in the neoplastic cells according to the modified grading scheme of Bloom and Richardson¹². The nodal status was analysed in 11/20 cases in primary tumors (*Table 1*).

Cells

MDA-MB-435 human breast cancer cells^{24,27,34,35} were cultured in Dulbecco Modified Eagle Medium (DMEM) (GIBCO) supplemented with 10% Fetal Calf Serum (FCS), 1 mM pyruvate and antibiotics free.

Materials and Antibodies

The purified TN preparations were obtained from Sigma and from Chemicon. Monoclonal anti-vinculin (clone No. hVIN-1 from Sigma Chemical Co.) and Phalloidin Rhodamin (Molecular Probes) were used. Two antibodies derived from two different clones, both of mouse origin: DB7 (BioGenex), and TN2 (DAKO) were used for immunohistochemical detection of TN. Biotin conjugated secondary antibody (AMERSHAM) and Streptavidin-FITC (AMERSHAM) were used for vinculin detection. For TN detection biotinylated secondary antibody (BioGenex), Streptavidin Peroxidase (BioGenex) and strept-ABCComplex-AP (DAKO) were used.

Immunofluorescence

MDA-MB-435 cells were grown for 24 h on glass coverslips in complete medium. Cells were treated for 10 min, 30 min 1h and 2h with 10, 20, 100, 200 µg/ml soluble TN. Cells were then rinsed with phosphate buffered saline (PBS), fixed with 1% paraformaldehyde /PBS 10 min, washed in PBS (3x), permeabilized with 0,04% Triton-X 2 min. and then stained with phalloidin rhodamin for 1h at room temperature. After washing in PBS (3x), cells were incubated with anti-vinculin monoclonal antibody (1:100 in PBS) for 1h at room temperature, washed in PBS (3x), incubated with goat anti-mouse IgG-biotin conjugate, diluted 1:100 in PBS for 30 min and finally incubated with Streptavidin-FITC diluted 1:100 in PBS for 1h. Coverslips were mounted with fluorescent mounting medium (DAKO) on glass slides. Negative controls were incubated in absence of primary antibody. Stained specimens were analysed on laser scanning confocal microscopy (MRC 1024, BIO-RAD).

For the *immunodetection* of TN, deparaffinized sections were treated with pepsin (0,1% in 0,01M HCl) for 50 minutes at 37°C. Antibodies were diluted to 1:40 and to 1:25 in PBS/bovine serum albumin (BSA)/ Sodium azide and sections were incubated for 90 minutes at 37°C. StrAviGen MultiLink (Biogenex), and StreptABCComplex-AP (DAKO) were used as secondary antibody. Immunoreaction was developed with New Fuchsin chromogen substrate (DAKO) respectively or with 20% 3,3'-diaminobenzidine in distilled water and 0,2% H₂O₂. Immunoreaction for TN was evaluated in the stroma in a distance of no more than 0.5 mm from the epithelial elements of the tumor. Two individuals examined all specimens and stromal TN positivity was given in %. The presence (+) or absence (0) of TN immunoreactivity was also scored for epithelial cells, vascular expression and positivity in normal ducts (*Table 2*). An average of the two observers' results was determined for each slide if interobserver difference was not greater than 20%, otherwise, slides were re-evaluated using multiheaded discussion microscopy (Olympus, BH2).

Results

15 of the 20 primary breast carcinomas were invasive ductal carcinomas, 3 of the 15 contained ductal carcinoma in situ component, 2 were of mixed type, one was invasive lobular carcinoma, one neuroendocrine carcinoma and one was invasive ductal carcinoma with Paget's disease. The

recurrences appeared between 1–10 years after surgery but in 9 cases the local recurrences were noted in the first two years after surgery.

Typically, the stromal TN expression was focal, often connecting the ducts of invasive ductal breast carcinomas. In some samples (5 cases) TN was not detected around all the ducts. TN was also observed around the

Table 2. Tenascin immunoreactivity and the analysed tumor types

Cases	Tumor type/year of diagnosis	TN expression/positivity			
		Stromal	Epithelial cell	In normal ducts	Vessels
1	- ILC/1996	0	0	0	0
	- IDC+ papillary carcinoma/1997	50–60%	0	0	+
2	- IDC /1995	80%	0	0	0
	- post-irradiation fibrosis +IDC/1997	20% in IDC	0	0	0
3	- IDC + ductal papillomatosis/1993	70–80%	0	+	0
	- IDC+ DCIS /1995	60–70%	0	0	0
4	- IDC+ DCIS/1994	10–20%	+	+	0
	- tubulo-lobular carcinoma/1995	10%	+	0	0
	- fibrocystic breast/1997	0	0	+	0
5	- IDC /1994	30–40%	+	+	0
	- recurrent IDC /1995	30%	0	0	0
	- second recurrency of IDC /1995	30%	0	0	0
6	- IDC /1994	5%	0	0	0
	- recurrent IDC /1996	30–40%	0	0	0
7	- IDC+DCIS /1994	5–10%	0	0	+
	- recurrent IDC +DCIS/1995	5%	0	0	+
8	- IDC+DCIS /1995	80%	+	0	+
	- recurrent IDC+ ILC/1997	30–40%	+	0	0
9	-Paget's disease + IDC/1995	5%	+	0	0
	- IDC+DCIS /1996	5–10%	0	0	0
10	- IDC /1996	20–30%	+	0	0
	- recurrent IDC /1997	10%	0	0	+
11	- IDC /1996	10–20%	0	0	0
	- recurrent IDC/1997	10%	0	0	0
12	- IDC /1996	70–80%	0	0	0
	- recurrent IDC /1997	70%	0	0	0
13	- IDC /1991	70–80%	0	0	0
	- recurrent IDC /1997	20%	0	0	0
14	- IDC + mucinosus carcinoma/1993	70%	+	0	0
	- recurrent IDC + mucinosus carcinoma/1997	70%	+	0	0
15	- IDC /1991	10–20%	+	0	0
	- recurrent IDC /1997	10%	+	0	0
16	-IDC +medullary carcinoma/1994	80–90%	0	0	0
	- recurrent IDC /1996	70–80%	0	0	+
	- recurrent IDC /1997	80%	0	0	0
17	- IDC /1995	70%	0	0	0
	- recurrent IDC/1997	60–70%	0	0	0
	- recurrent IDC/1997	50%	0	0	0
18	- IDC/1993	40–50%	0	0	+
	- recurrent IDC/1998	70–80%	+	0	0
19	- IDC /1989	50–60%	0	+	0
	- recurrent IDC / 1998	70%	0	0	0
20	- neuroendocrine carcinoma/1994	10–20%	0	0	+
	- IDC/1996	10%	0	0	0
	- recurrent IDC /1998	40–50%	0	+	0

tumor cell nests and around the ductal carcinoma in situ components of the invasive carcinomas. TN expression was also found in the wall of small arteries. In 4 cases TN was present in the primary breast carcinoma in the apical layer of some normal ducts. (*Figure 1*). There are no pub-

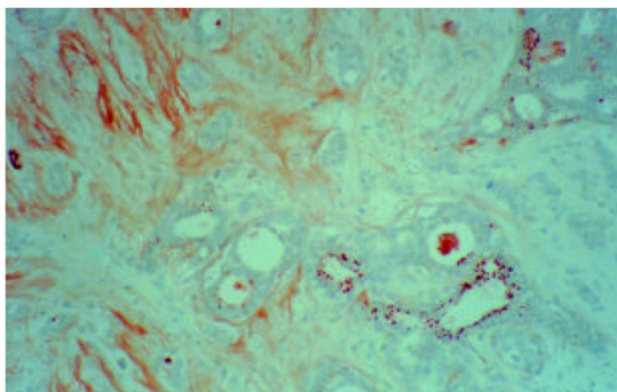


Figure 1. Paget's disease + invasive ductal carcinoma. Immunostaining for TN (DAKO) seen in the apical layer of normal ducts. (x20)

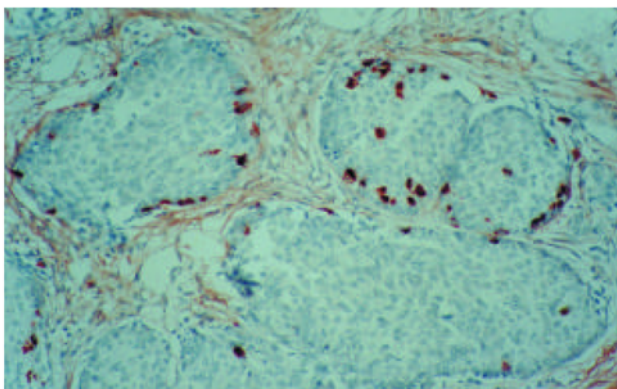


Figure 2. Invasive ductal carcinoma + mucinous carcinoma. Primary tumor. TN positivity in the tumor cells at the margins of tumor cell nests. (DAKO) (x20)

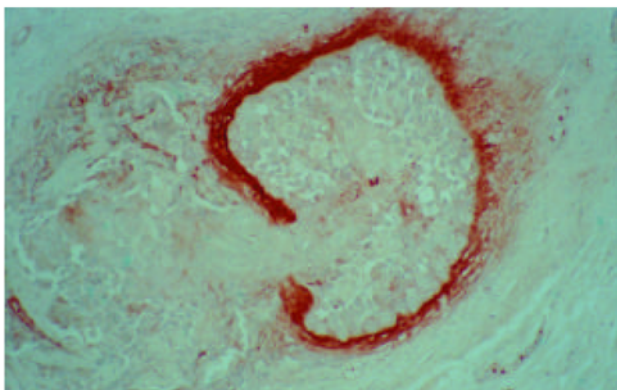


Figure 3. Paget's disease + invasive ductal carcinoma. The lack of TN at the invasion site. (DAKO) (x20)

lished data to suggest whether these cells are going to proliferate or not in a later phase. Compared to another series of ours³¹ in which 10 of 62 cases of primary invasive ductal breast carcinomas presented TN positive tumor cells, this series contained a high number of cases showing TN positivity in cancer cells (7/20 in primary tumors). These TN positive cells were scattered in tumors, usually at the periphery of tumor cell nests and in one case these TN positive cells formed a group (*Figure 2*). In one case microinvasion was observed with TN positivity around the affected ducts (*Figure 3*). TN expression was absent in the single analysed primary invasive lobular carcinoma. (*Table 2*)

The nodal status was analysed in 11 of 20 primary tumors and 6 of them showed metastatic tumor. Different histological grades of invasive ductal carcinomas did not differ in their distribution of stromal TN staining. We could not observe any correlation between the tumor size and stromal TN expression and between the stromal TN expression in primary and second primary or recurrent tumor. The weaker stromal TN positivity in some of the recurrent tumors may be explained by the reduced stromal component in second primary or recurrent tumors. There were no significant differences in staining between the two antibodies used for TN immunodetection.

The high stromal expression of TN in invasive ductal breast carcinoma, the TN positivity in epithelial cells, and in the apical layer of normal ducts provided us with the rationale to investigate the effect of TN on the organisation of filamentous actin cytoskeleton and focal adhesion complexes in the highly invasive MDA-MB-435 breast carcinoma cell line. The addition of soluble TN to the cell cultures did not cause a general rounding of tumor cells.

Soluble TN added to well spread breast carcinoma cell line in 10–20 µg/ml had no significant effect on focal adhesion plaques nor on phalloidin stained F-actin stress fibers. No significant effect was observed after a longer incubation. A slight tendency for reduction of the number of vinculin plaques was observed at a high concentration (100 µg/ml) of TN (*Figure 4a, b*). It is questionable whether human tumors express this protein in sufficient quantity to cause reduction in the number of vinculin plaques resulting in tumor cell migration. The examination was carried out with two different TN products simultaneously provided by two companies (Chemicon, Sigma), both reactions lead to the same results.

Discussion

In some tumors, the stroma accounts for a high proportion of the entire tumor mass. In tumors of the pancreas, stomach and breast the stroma may constitute more than 90% of the tumor. The tumorous stroma shows pronounced changes in ECM components as compared to normal tissue.¹⁸

In invasive ductal carcinomas TN expression is found predominantly in the stroma close to epithelial elements as opposed to normal and fibrocystic breast where TN is not expressed stromally. We also found TN expression in epithelial cells whereas others found a lack of epithelial TN expression.²⁸ Thus TN appears to be secreted by both epithelial and stromal elements close to the basement membrane zone.

The presence of TN in the tumor cells at the margins of tumor cell nests, in ducts, around tumor cell nests and around in situ carcinomas indicate that TN might be involved in cancer cell spreading, resulting in unfavourable prognosis. TN positivity in the apical layer of normal ducts is of questionable importance. Should TN be secreted by normal epithelial cells or these cells are in earlier stage of transforming into cancerous cells? Are these tumors of higher risk or not? Studies of higher numbers of cases (143) suggest that TN positivity in the invasion zone is the only prognostic marker in predicting local recurrences.¹⁶ Yoshida and co-workers³⁶ have found that cytoplasmic TN positivity indicate poor prognosis. Jähkola et al. found that the expression of TN in the invasion border was the only marker that predicted local recurrence. They also suggest that patients with carcinomas that do not express TN at the invasion border do not need adjuvant treatments.¹⁶ In a study by a Japanese group the analysed breast carcinomas were classified into three groups; cancer cell TN (+)/stromal TN (+), cancer cell TN (-)/stromal TN (+) and cancer cell TN (-)/stromal TN (-). They found that the group cancer cell TN (+)/stromal TN (+) exhibited an increased frequency of lymph node metastasis and poor outcome.¹⁵ Researchers investigating the capacity of malignant tumor cell lines to secrete TN have shown that TN was secreted by some tumor cells, especially those of epithelial origin.¹⁸

One consequence of modified ECM in tumors may be the increased invasive potential of tumor cells.¹⁸ TN and thrombospondin are considered to favour invasion and modulate sprouting of endothelial cells.^{2,19} TN, SPARC, and thrombospondin are considered to diminish the number of focal adhesions in bovine aortic endothelial cells.²⁵ However, the effect of TN on cells is undoubtedly more complex.

TN has been proven to control cell migration, and culture experiments have demonstrated that both epithelial and fibroblast cells spread less easily on a substrate coated with TN.^{1,25,29}

Alteration in cell shape after TN treatment has been reported in several studies and is related directly to the number and distribution of focal adhesions on the cell surface.^{7,25} This structure links ECM glycoproteins and proteoglycans to the cytoskeleton and its associated components via several types of integrin. How a molecule as large as a hexabranchion would be able to intercalate under the cells and how it acts on the extracellular surface of the focal adhesion, still remains controversial.

Interaction of TN with a cell surface molecule might trigger a cytoplasmic signal that alters the cytoskeleton. Since TN has been shown to alter the integrity of the actin cytoskeleton it is possible that this molecule modulates epidermal growth factor signalling through its effect on the actin cytoskeleton and focal adhesion molecules.²³

Publications regarding the attachment behaviour of some cell cultures have shown that cells secreting TN alone are round and float in suspension, while cells secreting FN only attach and spread quickly.^{9,13}

Some authors reported that TN reduces focal adhesion integrity in confluent endothelial and smooth muscle cells cultures.¹³ It was also found that TN causes a dose dependent reduction in the number of focal adhesion positive

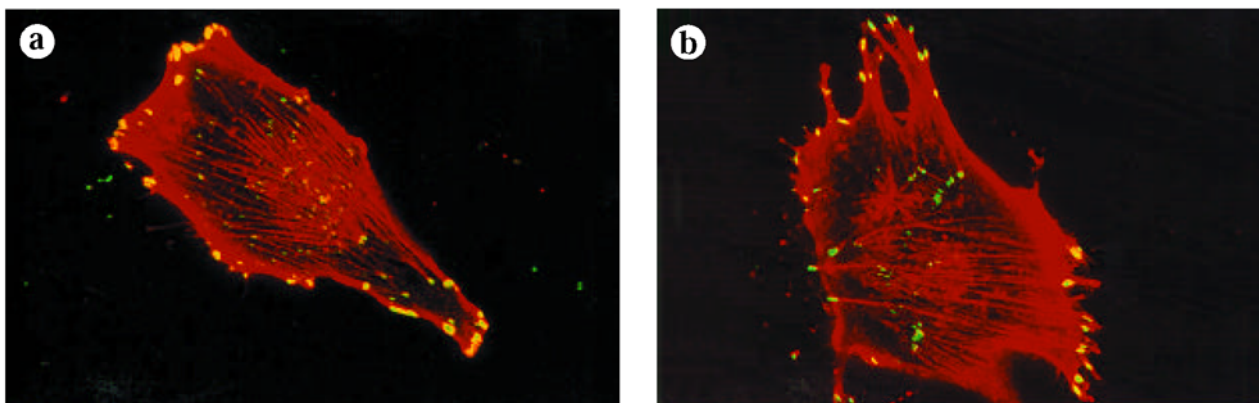


Figure 4. (a, b) Focal adhesion plaques (yellow-green fluorescence) and microfilament (red fluorescence) distribution in adherent MDA-MB-435 breast carcinoma cell line as detected by vinculin and rhodamine phalloidin. Adherent cells were fixed with 1% paraformaldehyde, permeabilized with Triton X-100. (a) Untreated tumor cells (b) Tumor cells treated with 100 µg/ml TN (Sigma), for 10 min. A slight tendency in reduction of the number of vinculin plaques compared to the untreated cells. Laser scanning confocal microscopy (MRC 1024, BIO-RAD) 4,2 cm 50 µm

cells to approximately 50% of albumin treated controls. A maximum response was reported with 20–60 µg/ml of soluble TN and the reduction in focal adhesion in TN-treated cells was observed after 10 min.²³

Cells adhere to the ECM proteins FN and TN in part via the interaction of certain integrins with the RGD sequence. Interaction between FN type III domains and beta1 integrins mediates focal adhesion kinase phosphorylation and focal contact adhesion.³ How the number of FN type III domains of TN influence the binding capacity of TN is questionable.

Our findings, in concordance with others,³² demonstrated that the addition of soluble TN-C to the medium had no or minimal effect on cells and cellular morphology, although the MDA-MB-435 human breast cancer cell line does express the v3 and 21 integrin which bind specifically to TN.^{27,29} The increased expression of stromal TN in invasive breast carcinoma and the lack of stromal TN in normal breast, the presence of TN in ducts and tumor cells may indicate the possible role played by TN in cancer development. The role of TN in cell-cell and cell-matrix interaction must be more complex and must be influenced by other extracellular components. However a higher number of cases should be studied to indicate the real prognostic importance of TN positivity. Other studies of the TN subtypes are also necessary. The questions of how TN interacts with other ECM components and how it influences the tumor cell migration, still remain unanswered.

Acknowledgements

We are grateful for the skilled technical assistance of A. Ladányi PhD., Á. Szik, K. Nagy, J. Ördögh. This study was supported by the Ministry of Public Welfare (Public Health Scientific committee grant number 134/ POT 97 T-01), OTKA grant number T-030254 and PhD grant (A-M. T.) of the Semmelweis University, Budapest.

References

- ^{1,2}Bourdon MA, Ruoslahti E: Tenascin mediates cell attachment through an RGD-Dependent Receptor. *J Cell Biol* 108:1149-1155, 1989.
- ²Canfield AD, Schor AM: Evidence that tenascin and thrombospondin-1 modulate sprouting of endothelial cells. *J Cell Sci* 108:797-809, 1995.
- ³Chi-Rosso G, Gotwals PJ, Yang J, et al: Fibronectin type III repeats mediate RGD-independent adhesion and signaling through activated beta1 integrins. *J Biol Chem* 272:31447-31452, 1997.
- ⁴Chiquet M, Fambrough DM: Chick myotendinous antigen II. A novel extracellular glycoprotein complex consisting of large disulfide-linked subunit. *J Cell Biol* 98:1937-1946, 1984.
- ⁵Chiquet-Ehrismann R, Mackie EJ, et al: Tenascin: an extracellular matrix protein involved in tissue interactions during fetal development and oncogenesis. *Cell* 47:131-139, 1986.
- ⁶Chiquet-Ehrismann R, Kalla P et al: Tenascin interferes with fibronectin. *Cell* 53:383-390, 1988.
- ⁷Chiquet-Ehrismann R, Kalla P, Pearson CA: Participation of tenascin and transforming growth factor- in reciprocal epithelial-mesenchymal interactions of MCF7 cells and fibroblasts. *Cancer Res* 49:4322-4325, 1989.
- ⁸Chiquet-Ehrismann R: Anti-adhesive molecules of the extracellular matrix. *Curr Opin Cell Biol* 3:800-804, 1991.
- ⁹Chiquet-Ehrismann R, Hagios C, Schenk S: The complexity in regulating the expression of tenascins. *BioEssays* 17:873-878, 1995.
- ¹⁰Choung C-M, Chen H-M: Enhanced expression of neural cell adhesion molecules and tenascin (cytotactin) during wound healing. *Am J Pathol* 138:427-440, 1991.
- ¹¹Crossin KL, Hoffmann S, Grumet M, et al: Site restricted expression of cytotactin during development of the chicken embryo. *J Cell Biol* 102:1917-1930, 1986.
- ¹²Elston CW, Ellis IO: Pathological prognostic factors in breast cancer. I. The value of histological grade in breast cancer: experience from a large study with long term follow up. *Histopathol* 19:403-410, 1991.
- ¹³Hahn AW, Kern F, Jonas U, et al: Functional aspect of vascular tenascin-C expression. *J Vasc Res* 32:162-174, 1995.
- ¹⁴Hibino S, Kato K, Kudoh S, et al: Tenascin suppresses CD3-mediated T cell activation. *Biochem-Biophys-Res-Commun* 250:119-124, 1998.
- ¹⁵Ishihara A, Yoshida T, Tamaki H, et al: Tenascin expression in cancer cells and stroma of human breast cancer and its prognostic significance. *Clin Cancer Res* 1:1035-1041, 1995.
- ¹⁶Jahkola T, Toivonen T, Virtanen I, et al: Tenascin-C expression in invasion border of early breast cancer: a predictor of local and distant recurrence. *British J Cancer* 78:1507-1513, 1998.
- ¹⁷Jaskiewicz K, Chasen MR, Robson SC: Differential expression of extracellular matrix proteins and integrins in hepatocellular carcinoma and chronic liver disease. *Anticancer Res* 13:2229-2237, 1993.
- ¹⁸Jessen LR, Petersen WO, Bissell MJ: Cellular changes involved in conversion of normal to malignant breast: importance of the stromal reaction. *Physiological Reviews* 76:69-125, 1996.
- ¹⁹Jones PL, Crack J, Rabinovitch M: Regulation of tenascin-C, a vascular smooth muscle cell survival factor that interacts with the v3 integrin to promote epidermal growth factor receptor phosphorylation and growth. *J of Cell Biol* 139:279-293, 1997.
- ²⁰Kawakatsu H, Shiurba R, Obara M, et al: Human carcinoma cells synthesize and secrete tenascin in vitro. *Jpn J Cancer Res* 83:1073-1080, 1992.
- ²¹Koukoulis GK, Howedy AA, Korhonen M, et al: Distribution of tenascin, cellular fibronectin and integrins in the normal, hyperplastic and neoplastic breast. *J Submicrosc Cytol Pathol* 25:285-295, 1993.
- ²²Mackie EJ, Chiquet-Ehrismann R, Pearson CA, et al: Tenascin is a stromal marker for epithelial malignancy in the mammary gland. *Proc Natl Acad Sci* 84:4621-4625, 1987.
- ²³Murphy-Ullrich JE, Lightenasciner VA, Aukhil I, et al: Focal adhesion integrity is downregulated by the alternatively spliced domain of human tenascin. *J Cell Biol* 115:1127-1136, 1991.
- ²⁴Price JE, Fabra A, Zhang RD, et al: Characterization of variants of human breast cancer cell line isolated from metastases in different organs of nude mice. *Int J Oncol* 5:459-467, 1994.
- ²⁵Sage HE, Bornstein P: Extracellular proteins that modulate cell-matrix interactions. SPARC, tenascin and thrombospondin. *J Biol Chem*. 266:14831-14834, 1991.
- ²⁶Sakakura T, Ishihara A, Yatani R: TN-C in mammary gland development: from embryogenesis to carcinogenesis. In *Regulatory Mechanism in Breast Cancer*, Lippman ME (ed) pp. 383-400. *Advances in cellular and molecular biology of breast cancer*. Kluwer Academic Publishers: Boston., 1991

- 27.²*Shaw LM, Chao C, Wewer UM, et al:* Function of the integrin alpha 6 beta 1 in metastatic breast carcinoma cells assessed by expression of a dominant-negative receptor. *Cancer Res* 56:959-963, 1996.
- 28.²*Shoji T, Kamiya T, Tsubura A, et al:* Immunohistochemical staining patterns of tenascin in invasive breast carcinomas. *Virchows Archiv A Pathol Anat.* 421:53-56, 1992.
- 29.²*Sriramarao P, Mendler M, Bourdon MA:* Endothelial cell attachment and spreading on human tenascin is mediated by alpha 2 beta 1 and alpha v beta 3 integrins. *J Cell Sci.* 105:1001-1012, 1993.
- 30.²*Taylor HC, Lightenasciner VA, Beyer WF, et al:* Biochemical and structurel studies of tenascin/hexabranhion proteins. *J Cell Biochem* 41:71-90, 1989.
- 31.²*Tökés A.M, Hortoványi E, Csordás Gy, et al:* Immunohistochemical localisation of tenascin in invasive ductal carcinoma of the breast. *Anticancer Res* 19:175-180, 1999.
- 32.²*Tremble P, Chiquet-Ehrismann R, Werb Z:* The extracellular matrix ligands fibronectin and tenascin collaborate in regulating collagenase gene expression in fibroblasts. *Mol Biol Cell* 5:439-453, 1994.
- 33.²*Vacca A, Ribatti D, Fanelli M, et al:* Expression of tenascin is related to histologic malignancy and angiogenesis in b-cell non-Hodgkin's lymphomas. *Leuk Lymphoma* 22:473-481, 1996.
- 34.²*Wewer UM, Shaw LM, Albrechtsen R, et al:* The integrin alpha 6 beta 1 promotes the survival of metastatic human breast carcinoma cells in mice. *Am J of Pathol* 151:1191-1198, 1997.
- 35.²*Wong NC, Mueller BM, Barbas CF, et al:* Alphav integrins mediate adhesion and migration of breast carcinoma cell lines. *Clin Exp Metastasis* 16:50-61, 1998.
- 36.²*Yoshida T, Ishihara A, Hirokawa Y, et al:* Tenascin in breast cancer development-is epithelial tenascin a marker for poor prognosis. *Cancer Lett* 90:65-73, 1995.
- 37.²*Yoshida T, Matsumoto E, Hanamura N, et al:* Co-expression of tenascin and fibronectin in epithelial and stromal cells of benign lesions and ductal carcinomas in the human breast. *J Pathol* 182:421-428, 1997.