

## CASE REPORT

**New Human *Dirofilarioses* in Hungary**

Gábor ELEK,<sup>1</sup> Károly MINIK,<sup>2</sup> László PAJOR,<sup>3</sup> Gyula PARLAGI,<sup>4</sup> István VARGA,<sup>5</sup> Ferenc VETÉSI,<sup>6</sup>  
János ZOMBORI<sup>7</sup>

Departments of Pathology, <sup>1</sup>Central Railway Hospital, Budapest, <sup>2</sup>County Hospital, Miskolc,  
<sup>3</sup>Medical University, Pécs, <sup>4</sup>Municipal Hospital, Dél-Pest, <sup>6</sup>Veterinary University, Budapest, <sup>7</sup>Municipal Hospital,  
Hódmezővásárhely and the <sup>5</sup>Parasitological Department of Veterinary University, Budapest, Hungary

About ten cases of filariosis have recently been recorded in the Hungarian medical literature, six of them caused by *Dirofilaria repens*. *Dirofilaria repens* is a mosquito-transmitted filaroid worm in the subcutaneous tissue of dogs and cats in the temperate areas of the Old World. It accidentally infects man, too, and can remain unidentified due to physicians' poor knowledge of the parasite. In the last two years six new *Dirofilaria repens* infections have been found in various parts of the coun-

try: five localised dermally and one in the deep tissues. Two of the cases might have been acquired in Italy during summer travels. Four patients, however, have never been abroad, these cases must be considered autochthonous infections. The thickness of the multilayered cuticle of the worm, diameter of the body and the size, form and number of the longitudinal ridges on its surface are used in the histological diagnosis of the parasite. (Pathology Oncology Research Vol 6, No 2, 141–145, 2000)

**Keywords:** parasite, zoonosis, mosquito transmitted, *Dirofilaria repens*, histology

**Introduction**

Dirofilariosis is an infection with different worm species of *Dirofilaria*. In Hungary this is mostly *Dirofilaria (Notchiella) repens*. This zoonosis is spread by mosquitoes. The natural hosts are dogs (rarely cats, foxes and other carnivores).<sup>3</sup> Most human infections are localised in the skin as a result of mosquito bite.<sup>18</sup> Diagnosis is a pathological or parasitological task but in most textbooks (the Hungarian pathologists are familiar with) this kind of filaria is not included in such a detailed form that it could be identified. The aim of this paper is therefore to present the latest cases in order to aid the diagnostic process.

**Material and Methods**

Buffered formalin fixed tissue was paraffin embedded and sections were HE and PAS stained. Occasionally connective tissue stains: Van Gieson, Masson and the Goldner

modification of Masson were used. Measurement of microscopic lengths was carried out comparing an ocular scale to standard objects with known dimensions.

**Case 1**

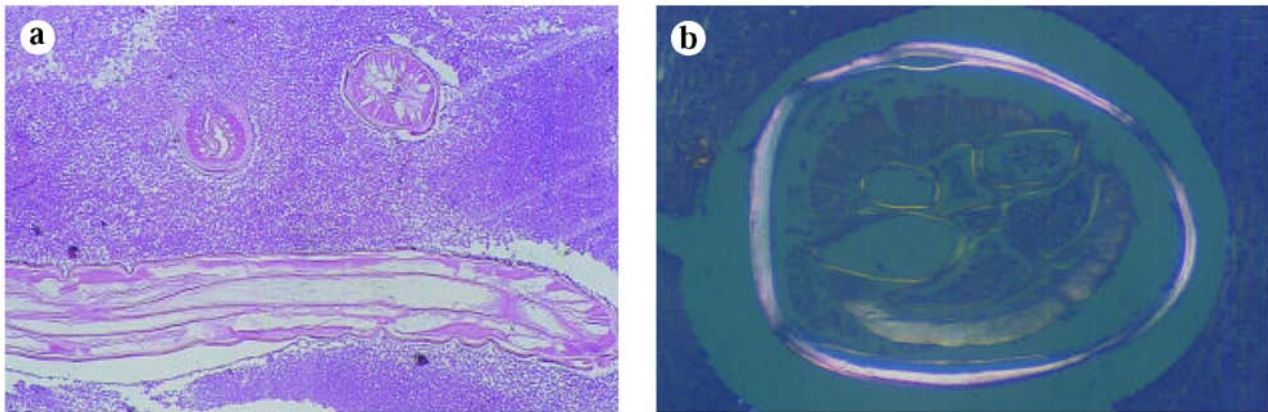
A 52-year-old woman complained of the swelling of her right eyelid. The ophthalmologist palpated a movable, rubbery mass at the lower edge of the orbit. At removal its diameter proved to be 15 mms and the mass reached deeply in the orbit. Microscopically many transsections of a worm surrounded by eosinophil and neutrophil granulocytes could be seen. At the periphery round cell infiltration was in the loose connective and fatty tissue. The diagnosis was infection by a male *Dirofilaria repens*. The patient had not been abroad. She had two dogs, but these were free of *Dirofilaria*. She often stayed in her cottage at the river Danube near Budapest, where there were many mosquitoes in the summer. She liked animals and was also engaged in breeding them.

**Case 2**

A 48-year old fisherman (occasionally even a hunter) came with a 2 cm movable swelling on the border of his hair and skin of the brow. It was removed as an

Received: Febr 10, 2000, revised: April 5, 2000; accepted: April 28, 2000

Correspondence: Gábor ELEK, M.D., Ph.D., Dept of Pathology at Central Hungarian Railway Hospital, Podmaniczky u 111., H-1062 Budapest, Hungary. Tel: (36) (1) 269 5656, fax: (36) (1) 265 5579



**Figure 1.** a) Longitudinal and cross sections of *Dirofilaria repens* among leukocytes. Three layers of the cuticle are discernible, 5x. b) Birefringence of the cuticle in polarised light, HE, 20x.

atheroma. The cyst was opened at the operation and a 8 cm long worm was pulled out. By histology *Dirofilaria repens* was diagnosed. The sex was probably female (it could not be defined with absolute certainty as the worm had been injured at the extraction, see *Figure 6/a*). The man had not been in any foreign country but lives in a country-town (Hódmezővásárhely) at river Tisza, where in the backwaters mosquitoes were swarming in the summer.

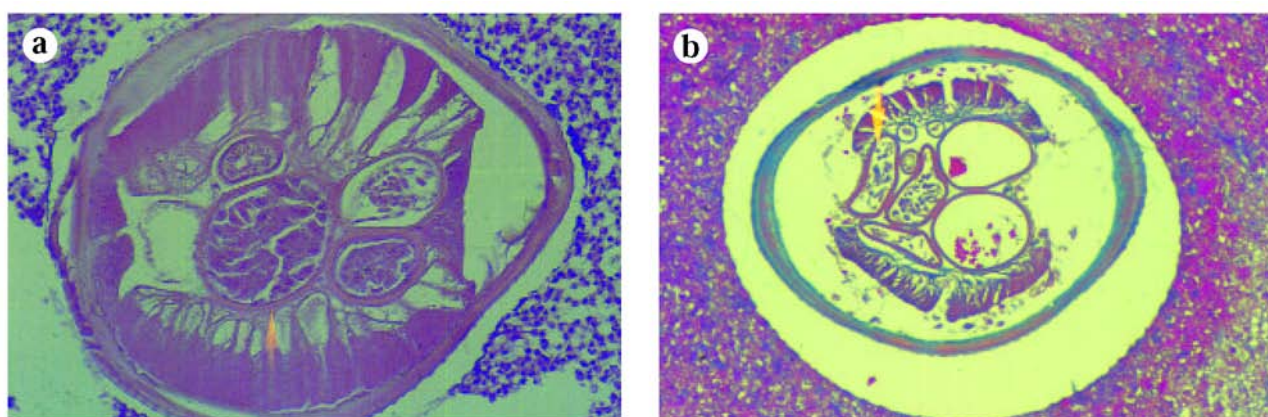
#### Case 3.

A 64-year-old woman felt a stabbing pain at the border of her back and pelvis in line with her armpit. Later a swelling appeared there, it reddened and in the end it became painful. Histology found a granuloma with a

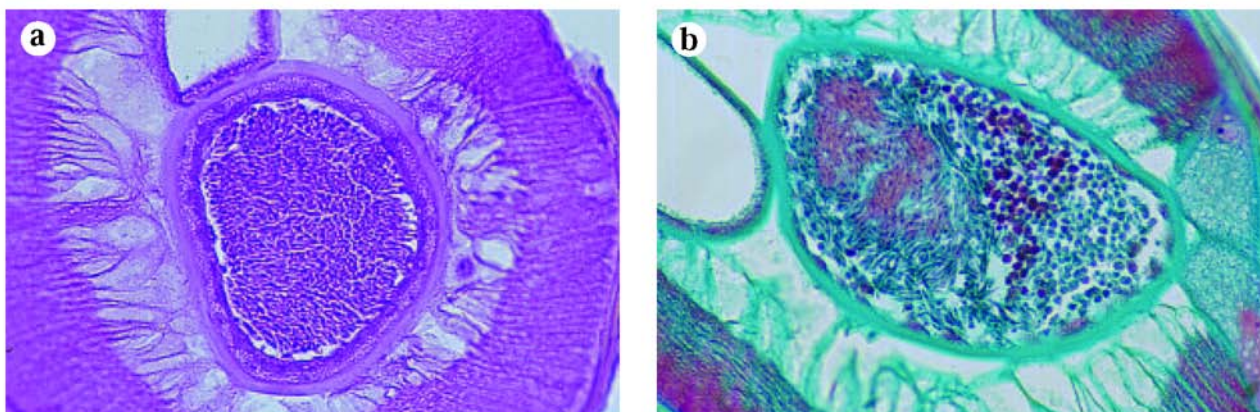
female *Dirofilaria repens* in it. The woman, who was living in a village (Szegilong) near the town Miskolc, had a little dog. She had not been out of Hungary. When the stabbing pain appeared she was staying in Budapest for some days. The river Tisza at her dwelling place had many spots of stagnant water and mosquitoes.

#### Case 4.

A painful, abscess-like nodule with 2 cm in diameter was excised from the inner side of the right upper arm of a 76-year-old woman. Histologically among eosinophil granulocytes the cross section of the posterior end of a young (350 µm wide) female *Dirofilaria* could be seen. The superficial ridges were characteristic of a *Dirofilaria repens*, but they were discernible only on a narrow sec-



**Figure 2.** a) In the cross section of the worm many tubes are seen. The smallest of them with thick wall is the intestine, the others are sex organs. The females contain double sex organs. Therefore, at least two tubes are visible in the coeloma (body cavity). At the anterior and posterior end of the body the female sex tubes are coiled, thus more than two lumina can be seen sometimes. In the uterus (arrow) and oviducts are the variously developed oocytes. The muscles are undetached from the cuticle. This and the leukocytes point to a fresh infection, only some months old. HE. b) Musculature is detached from the cuticle, showing long time dead worm, i.e. old infection. In the uterus (arrow) fully developed eggs of microfilaria can be seen. Several layers of the cuticle and longitudinal ridges are discernible on the surface, Masson, 20x.



**Figure 3.** **a)** In the cross section of a male worm, only one tube is seen beside the intestine because the male sex organ is single. A cell is visible in the muscle layer which points to alive state of the worm at the time of the fixation. HE. **b)** The spermatozoa in the male sex tube are variously developed. In the continuation of the muscle layer the spongy blue tissue with two nuclei is the so called lateral chord. Thickening of the internal layer of the cuticle is seen in the lateral chord. Masson-Goldner, 40x.

tor of the cuticle. The woman was living in a village (Csobaj) near the town Miskolc between the river Tisza and the canal Takta. She had never been abroad.

#### Case 5.

Under the lower eyelid at the upper border of the maxilla, an ulcerated tumor was removed from a 71-year-old woman. Histological diagnosis was a granuloma caused by a female *Dirofilaria repens*. The patient had both a dog and a cat. Near her flat were there fishing ponds and the water clearing works of the town of Pécs. In addition she had been in Italy around Rome, as a tourist half a year before her lesion appeared.

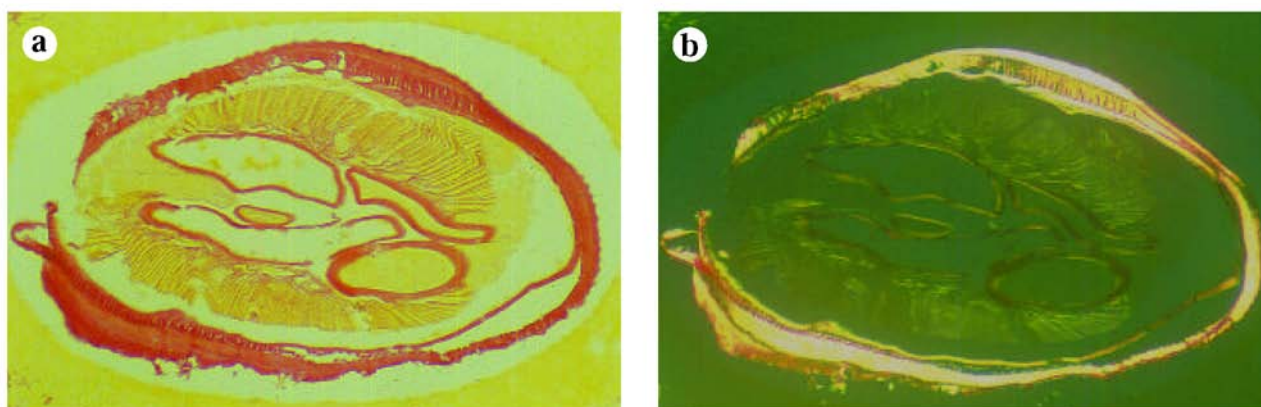
#### Case 6.

A 37-year-old man complained of a swelling in his right testis. A small painful nodule was palpated there. After orchietomy, a 3x2x2 cm yellow nodule attached to the

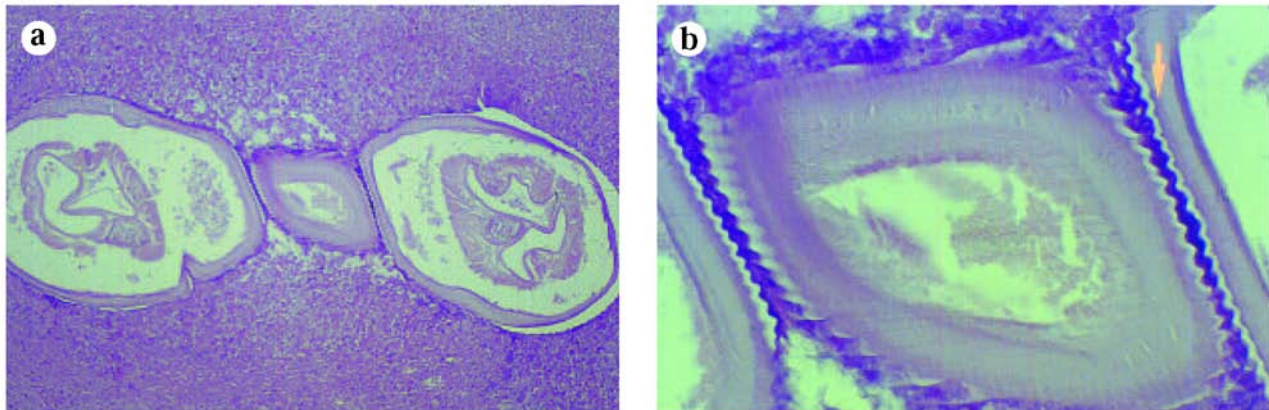
spermatic cord was found. In sections it proved to be a foreign body granuloma with transection of a female *Dirofilaria repens* in the centre. The young man had a dog and a house but he lived in many places in the whole country - as his profession was railwayman. Five years earlier he had spent several weeks in Italy in the Po valley.

#### Discussion

*Dirofilaria repens* is endemic in the Mediterranean,<sup>2,4,9,11</sup> and only in the old world. It has been studied most extensively in Italy. This is the reason why we cite Italian publications and the allusion to the rich illustrative documentation. The most widely used handbooks of human pathology discuss other filariae in the first place. English textbooks mention *Wuchereria bancrofti*, the American ones discuss *Dirofilaria tenuis*, *D. ursi* and *D. immitis*, because these are the most frequent species in their regions.<sup>5,10,18</sup> In Hungarian medical literature *Dirofilaria* infection has now



**Figure 4.** **a)** Connective tissue stains make visible even the long dead worm. **b)** In polarised light, the fibers of the cuticular layers are discernible, running oblique to the axis of the body, and perpendicular to each other in successive layers. Van Gieson, 20x



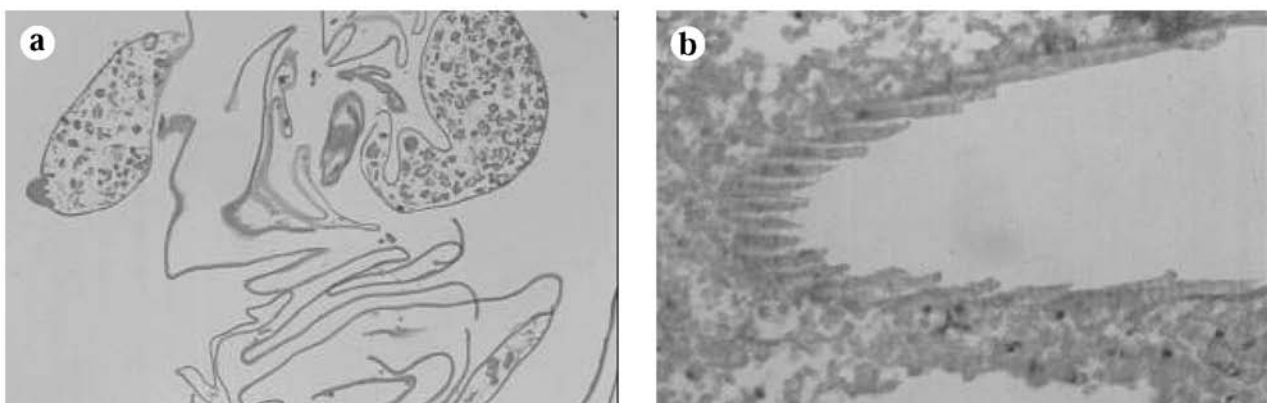
**Figure 5.** a) Crosssection of an U shape like coiled female worm, 5x. b) In the middle part of the section the size of the longitudinal ridges on the surface of the cuticle can be seen, 40x, HE.

and then been mentioned since the end of the last century.<sup>6</sup> In these first publications the documentation does not exclude infection with other filaria species, not with *Dirofilaria repens*. Until now it has been thought that human *Dirofilaria repens* cases diagnosed in our country were acquired abroad,<sup>8</sup> as assumed also in Austria<sup>3</sup> or in Norway.<sup>19</sup> In our 5th and 6th cases this might really have been the source of infection. Not so in the first four cases. On the grounds of locally acquired infection we have to suppose the presence of infected dogs in Hungary from which mosquitoes are transmitting the worm. Thus, the danger exists that the worm will become endemic here. The first four patients had never been abroad, they liked animals and they often stayed at places where mosquitoes could multiply in water: they must have been infected in our country. Indeed, a veterinary survey has shown *Dirofilaria repens* infection of Hungarian dogs around the town Szekszárd,<sup>20</sup> and the % of infected dogs agrees well with the Italian data.<sup>1,10</sup> It is not excluded that the worm could

have been imported with the dogs of foreign (Italian and German) hunters.<sup>21</sup> Tourism also supports its spread.

After a mosquito bite the infective stage larvae get into the subcutis. The infection is mostly symptomless, but after some days itching, hyperaemia, erythema, oedema, i.e. signs of a banal inflammation may appear. These may last for some weeks and in the end a little nodule appears which might slowly migrate with the worm inside.<sup>12,15,17</sup> In the swelling, there are many granulocytes (mostly eosinophils, cases 2-5, *Figures 1a, 2a*).

Some 10-20% of the infections take place in the eye<sup>7,14,15,16</sup> (eyelids or subconjunctival localisation, case 1.). Formerly *Dirofilaria* (or *filaria*) *conjunctivae* was the synonym for *Dirofilaria repens*. The symptoms are completed by foreign body feeling and in some cases by sharp, almost unbearable pain. If the worm gets under the cornea, blindness may sometimes develop. The slow spiral movement of the worm is apparent through the cornea or in the conjunctiva.<sup>15,16</sup> If the subcorneal localisation remains



**Figure 6.** a) Since the sex organs are anchored at only one point in the whole body (vagina in females, cloaca in males) they are often dislodged by cutting the worm at operation or embedded in paraffin blocks. Here the uterus is spread outside the worm, 20 x. b) During handling the section, the nematode came off leaving the indentations of the surface ridges in the surrounding fibrin like a cogged wheel, 40 x, HE.

unobserved, diagnostic pitfall may be the result. Simple conjunctivitis, herpesvirus keratitis, and even sinusitis maxillaris were the false diagnoses.<sup>10</sup>

Sometimes the worm gets into the deeper tissues with lymphatic flow or by active movement (in the lung<sup>13</sup>, the muscles, breast<sup>1</sup>, or genital organs<sup>8</sup>), but this is characteristic for other *Dirofilaria* species (*Dirofilaria immitis*, *Wucheria bancrofti*),<sup>5,9,18,20</sup> In such cases dirofilariosis may manifest itself only after years of the infection, when the worm has already died (*Figure 2b*) and a regular foreign body granuloma has been formed around it (case 6).

In infected humans, copulation of the worms does not generally occur as in dogs. Microfilariosis does not develop, and therefore chemotherapy<sup>4,20</sup> is unnecessary. Therapeutic intervention is operation by a surgeon, dermatologist, ophthalmologist or urologist: it consists of removal of the worm. If it is carried out *in toto* the parasitologist may identify *Dirofilaria repens* immediately by its 6–15 cm length, by the characteristics of the mouth, anus, etc. In histological section the worm is 250–650 µm wide, its outer cuticle cover is 10–15 µm deep and consists of at least 3 layers (*Figures 1b, 3a,b, 4a,b*). The most typical is the surface, showing about 100 longitudinal crests along the whole body. These are 1–3 µm high, 3–4 µm wide and are 6–10 µm apart (*Figures 5a,b; 6b*).

The final diagnosis is a pathological and parasitological task. In our report we should like to remind the clinician to ask the patient whether he has been (and when and where) abroad, whether he has animals (dog, cat) and whether he lives near a watershore where mosquitoes multiply. The answers may contain new and useful data for parasitologists concerning the spread of the worm in Hungary.

#### Acknowledgements.

We thank for the technical assistance of Susan Pintér.

#### References

- 1.<sup>2</sup>Ashford RW, Dowse JA, Rogers WN, et al: *Dirofilariosis* of the breast. *The Lancet*, 1:1198, 1989.
- 2.<sup>2</sup>Avdiukhina TI, Supriaga VG, Postnova WN: *Dirofilariosis* in the countries of the CIS 1915–1996. *Medsk Parazitol* (Russia) 4:3–7, 1997.
- 3.<sup>2</sup>Bardach H, Heimbucher J, Raff M: Subkutane *Dirofilaria (Nochtiella) repens*-Infection beim Menschen – Erste Fallbeschreibung in Österreich und Übersicht der Literatur. *Wien Klin Wschr* 93:123–127, 1981.
- 4.<sup>2</sup>Boreham PFL, Atwell RB: *Dirofilariosis*. CRC Press, Boca Raton, Florida, 1988.
- 5.<sup>2</sup>Gutiérrez Y: Diagnostic features of zoonotic filariae in tissue sections. *Human Pathology* 15:514–525, 1984.
- 6.<sup>2</sup>Kotlán A: On a new case of human filariidosis in Hungary. *Acta Vet Acad Sci Hung* 1:69–79, 1951.
- 7.<sup>2</sup>Németh B, Kugler S: Ophthalmo-filariasis. *Orvosi Hetilap* 109: 195–197, 1968.
- 8.<sup>2</sup>Pampiglione S, Elek G, Pálfi P, et al: Human *Dirofilaria repens* infection in Hungary: a case in the spermatic cord and a review of the literature. *Acta Vet Acad Sci Hung* 47:77–83, 1999/a.
- 9.<sup>2</sup>Pampiglione S, Rivasi F, Canestri Trotti G: Pitfalls and difficulties in histological diagnosis of Human *Dirofilariosis* due to *Dirofilaria (Nochtiella) repens*. *Diagn Microbiol Infect Dis* 34:57–64, 1999/b.
- 10.<sup>2</sup>Pampiglione S, Bortoletti G, Fossarello M, et al: *Dirofilariosis* umana in Sardegna: 4 nuovi casi. *Pathologica* 88:472–477, 1996/a.
- 11.<sup>2</sup>Pampiglione S, Brollo A, Ciancia EM, et al: *Dirofilariosis* umana sottocutanea, 8 ulteriori casi in Italia. *Pathologica* 88:91–96, 1996/c.
- 12.<sup>2</sup>Pampiglione S, Canestri Trotti G, Rivasi F, et al: Human *dirofilariosis* in Greece: a review of reported cases and a description of a new, subcutaneous case. *Ann Trop Med Parasitol* 90:319–328, 1996/b.
- 13.<sup>2</sup>Pampiglione S, Rivasi F, Paolino S: Human pulmonary *dirofilariosis*. *Histopathology* 29:69–72, 1996/d.
- 14.<sup>2</sup>Pampiglione S, Azzaro S, Bongiorno A, et al: La *dirofilariosis* oculare umana in Italia: descrizione di 6 nuovi casi. *Revisione della casistica Italiana. Annali di Ottalmologia e Clinica Oculista*. 121:257–277, 1995.
- 15.<sup>2</sup>Pampiglione S, Arlotta MR, Ambrosio ED, et al: La *dirofilariosis* umana nel sud d'Italia. I. Regione Puglia. *Pathologica* 86:528–532, 1994.
- 16.<sup>2</sup>Pampiglione S, Fruttaldo L, Mongio F, et al: Due casi clinici di *filariosis* zoonotica da probabile *Dirofilaria repens*. *Pathologica* 85:521–524, 1993.
- 17.<sup>2</sup>Parlagi Gy, Sumi Á, Elek G, et al: Szemüregi *dirofilariosis*. *Magyar Szemészet*, In press, 2000. (in Hungarian only)
- 18.<sup>2</sup>Portnoy LG: *Dirofilariosis*. In: *Pathology of infectious diseases*. (Eds: Connor DH, Chandler FW, Schwartz DA et al) Appleton and Lange, 1997, vol 2, pp1391–1396.
- 19.<sup>2</sup>Settnes OP, Engebjerg E: Human subcutaneous *dirofilariosis* caused by *Dirofilaria repens*. *Apmis* 99:364–370, 1991.
- 20.<sup>2</sup>Szél Z, Sréter T, Csikós K, et al: Autochton *Dirofilaria repens* fertőzöttség kutyákban. *Magy Áo Lapja* 121:100–104, 1999. (in Hungarian only)
- 21.<sup>2</sup>Zahler M, Glaser B, Gothe R: Eingeschleppte Parasiten bei Hunden: *Dirofilaria repens* und *Dipetalonema reconditum*. *Tierarzt Prax* 25:388–392 1997.