

ARTICLE

Apoptosis and p53 Expression in Human Gliomas

László SIPOS,¹ Zsolt SZEGEDI,² Imre FEDORCSÁK,¹ Dénes ÁFRA,¹ Béla SZENDE²

¹National Institute of Neurosurgery, Budapest; ²First Institute of Pathology and Experimental Cancer Research, Semmelweis University of Medicine, Research Unit for Molecular Pathology, Joint Research Organisation of the Hungarian Academy of Sciences and the Semmelweis University of Medicine, Budapest, Hungary

Twenty-five human gliomas of different histological grade and type were studied for p53 expression by immunohistochemistry and for apoptosis using ApopTag™ method. p53 expression (percentage of positive cells) was highest in anaplastic astrocytomas, followed by low grade astrocytomas and surprisingly in glioblastomas. Granular cytoplasmic p53 positivity appeared in 4/5 low grade oligodendroglioma and in 2/5 low grade mixed oligoastrocytomas. The means of apoptosis index in the

Key words: apoptosis, p53 expression, gliomas, grade

different tumor types ranged between 0.8 and 11.5 with the highest values in anaplastic astrocytoma and glioblastomas. Although the number of cases per group were relatively low and the individual values showed differences it seems that p53 expression is related to the biological aggressiveness of gliomas. It is also suggested that high level of apoptosis in malignant glioma could represent a p53 independent pathway. (Pathology Oncology Research Vol 4, No 4, 267–270, 1998)

Introduction

Anaplastic astrocytomas and glioblastomas are the most frequent hemispherical neoplasms, which together with the less malignant low grade astrocytomas represent 57–60% of all primary intracranial tumours.²⁵ Unfortunately, astrocytic tumors are of infiltrative character and radical removal is not possible. Moreover, a considerable proportion of relatively less malignant tumours are prone to obtain a more malignant phenotype which increases the frequency of anaplastic, dedifferentiated tumours at recurrence.^{2,28}

Despite of the recent advances in neuroradiology and postoperative radio- and adjuvant chemotherapy the prognosis of gliomas still remains poor.^{1,3,4,6,8,9,10,13,14,20,32} Development of immunohistochemical techniques provid-

ed better understanding of the biological properties of gliomas and the use of monoclonal antibodies both in diagnosis and therapy shows promise.^{5,27,31,32} Genetic changes causing loss of active cell death (i.e. apoptosis) are likely to be critical components of tumorigenesis. Cell cycle control and cell death appear to be tightly linked processes and p53 is an example of a gene product which affects both cell cycle progression and apoptosis. Tumor inhibition by p53 could be due to the activation of cell death program in tumor cells.^{15,19,25,29}

Alterations of p53 have been observed in human astrocytomas of each histological grade, suggesting that this event may occur early in the genesis of these tumors.²⁶ Mutation of TP53 gene, which is one of the most frequent genetic alterations in human malignancies, including gliomas, is often associated with overexpression of the p53 protein. Correlation between the number of p53 protein immunopositive cells and histological grade of astrocytomas has been reported, though mutations of TP53 gene were independent of tumour grade. On the other hand, overexpression of p53 protein occurs without detectable TP53 mutation in astrocytomas.^{17,18} Our aim was to study p53 expression and the rate of apoptosis in various types of human gliomas.

Received: June 22, 1998; accepted: Nov 10, 1998

Correspondence: Prof Béla SZENDE, 1st Institute of Pathology and Experimental Cancer Research, Semmelweis University of Medicine, Üllői u. 26, 1085 Budapest, Hungary. Tel: +36-1-266-0451; fax: +36-1-317-1074.

The work was supported by OTKA 17722, 17849, 22551, 22555 projects (for B. Szende).

Materials and methods

Tumor samples

Twenty-five human gliomas of different type and histological grade were examined in formalin fixed, paraffin embedded sections. The specimens were classified according to the WHO classification.¹⁶ Five tumors in each following group were selected; benign (low grade) astrocytoma (grade 2), anaplastic astrocytoma (grade 3), glioblastoma multiforme (grade 4), grade 2 oligodendroglioma and grade 2 mixed oligoastrocytoma. The survival time of the patients following the surgical removal of the gliomas was known in all cases.

Immunohistochemistry

For immunohistochemical detection of p53 monoclonal mouse anti-human p53 protein (DAKO, Code No M 7001) was used. This antibody detects both wild type and mutant p53. Because the half-life of wild type p53 is very

Table 1. Gender, age, type of glioma, survival time, p53 expression and apoptotic ratio in the tumor tissue of 25 cases with glioma

Name	Sex	Age	Grade	Survival time (weeks)	p53 (%)	Apoptosis (%)
1.	m	38	O2	296	+	1,3
2.	m	45	O2	186	1.0	3.0
3.	f	44	O2	432	+	1.0
4.	m	33	O2	409	+	2.1
5.	m	37	O2	409	1.8	
6.	f	30	AO2	230	+	2,4
7.	m	23	AO2	490	+	0.4
8.	f	51	AO2	122	5.0	2.9
9.	m	29	AO2	634	20.0	0.3
10.	m	48	AO2	369	15.0	0.5
11.	m	27	A2	201	20.0	0.9
12.	f	39	A2	373	50.0	0.6
13.	f	46	A2	232	10.0	0.5
14.	f	41	A2	238	50.0	1.2
15.	m	31	A2	159	50.0	0.9
16.	m	36	A3	16	35.0	1.2
17.	m	39	A3	73	80.0	15.8
18.	f	46	A3	50	1.0	0.9
19.	f	53	A3	84	80.0	4.4
20.	f	37	A3	51	80.0	2.9
21.	f	59	GBM	82	1.0	12.8
22.	f	32	GBM	53	50.0	32.2
23.	m	36	GBM	25	0.0	9.6
24.	f	46	GBM	48	1.0	2.2
25.	m	61	GBM	38	5.0	0.9

O2: grade 2 oligodendroglioma, AO2: grade 2 mixed oligoastrocytoma, A2: grade 2 astrocytoma, A3: grade 3 astrocytoma, GBM: glioblastoma multiforme, +: granular cytoplasmic positivity

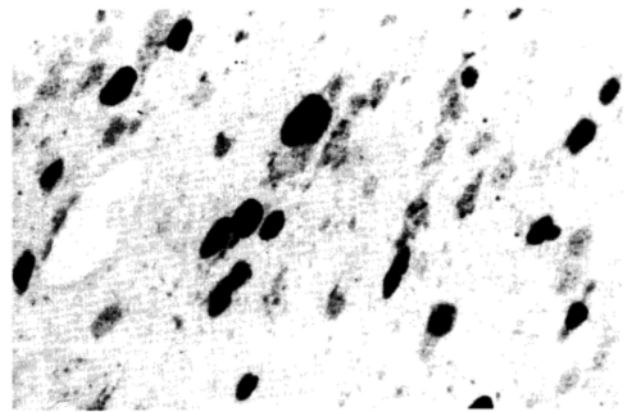


Figure 1. P53 positivity in malignant astrocytoma.

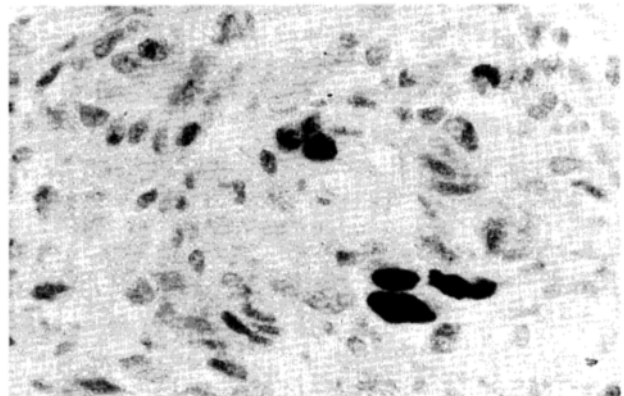


Figure 2. Few p53 positive nuclei and faint granular cytoplasmic staining in oligodendroglioma.

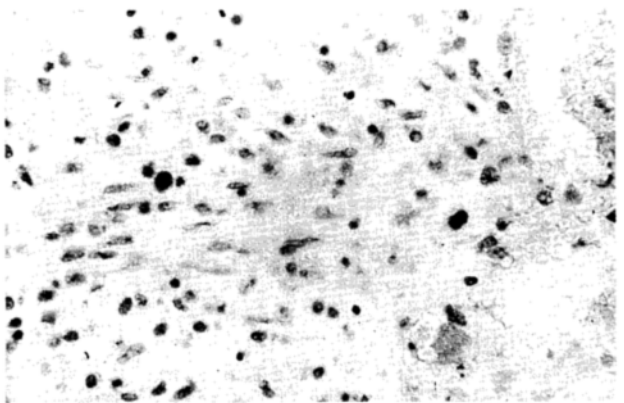


Figure 3. Low number of apoptosis in grade 2 astrocytoma (Apop-tag)

short compared to that of mutant p53, the positivity using this antibody represents mainly mutant p53. The binding of the anti-human p53 protein to the cells was detected by DAB. The labelling index for p53 positive cells was determined by counting 1000 tumor cells randomly.

Apoptosis was determined by using ApopTagTM *in situ* apoptosis detection kit (Oncor, Inc. Code No S 7100) by




Figure 4. High number of apoptosis in glioblastoma multiforme (Apop-tag).

direct immunoperoxidase detection of digoxigenin labelled genomic DNA. Apoptotic index was calculated as apoptotic tumor cells/1000 tumor cells.

Microsoft Excel 5.0 was used for statistical analysis.

Results

The percentage of p53 positive cells were highest in anaplastic astrocytomas, and the lowest – unexpectedly in glioblastomas (Table 1.). Figure 1 shows p53 positive cells in an anaplastic astrocytoma. In mixed low grade oligoastrocytomas two cases (2/5) showed faint cytoplasmic granular positivity, and type of reaction was observed in most (4/5) oligodendrogliomas (Figure 2). Although the number of cases is low and the individual differences are rather wide, it seems, that the decreasing survival rate from low grade oligodendroglioma to anaplastic astrocytoma correlates with increasing p53 protein expression, except in glioblastomas.

The apoptosis index (AI; the percentage of apoptotic cells) was low in A2, higher in A3 astrocytomas and highest in glioblastomas (Table 1.). Figures 3 and 4 show apoptotic cells in low grade glioma and glioblastoma multiforme. Low values (below 2%) were found in oligoastrocytomas and oligodendrogliomas.

Discussion

Neoplasms derived from astrocytes constitute the majority of primary brain tumors. They exhibit several cytogenetic abnormalities involving loss or structural rearrangement of loci on chromosomes 9, 10 and 17.²² The loss of function of p53 can contribute to the survival and accumulation of cells with increasing number of gene errors – due to the loss of suppressor function and the capacity to induce apoptosis.¹⁵ Obviously many other factors play role in malignant transformation and progression.

A study on apoptosis, Ki-67 immunolabelling and accumulation of bcl-2 and p53 proteins in different astrocytomas showed correlation between the median apoptosis index and higher grade of tumors, but no clear relationship between AI and bcl-2 or p53 was evident.⁷ Apoptotic index in different grade and type of neuroepithelial tumors was studied by Schiffer et al.^{23,24} We found that the immunohistochemically detectable and presumably mutant p53 protein expression increases with the grade of oligodendrogliomas, oligoastrocytomas and in astrocytomas. Interestingly, p53 expression decreased in glioblastomas, which due to the loss or further mutation of TP53 gene. It may be also assumed that in glioblastoma apoptosis follows a p53-independent pathway. Cytoplasmic expression of p53 in oligodendrogliomas and oligoastrocytomas may represent translocation of the protein.

The number of apoptotic cells was relatively low, irrespective of p53 expression, in oligodendroglioma, mixed oligoastrocytoma and both types of astrocytomas. Only glioblastomas had a high apoptotic index, which may suggest in this tumor type the apoptosis is p53 independent. Nevertheless, the increased rate of apoptosis does not prevent the rapid progression of glioblastoma multiforme.

References

1. Áfra D, Kocsis B, Kerpel-Frónius S, et al: Dibromodulcitol-based combined postoperative chemotherapy of malignant astrocytomas and glioblastomas. *J Neuro-Oncol* 4:65-70, 1986.
2. Áfra D, Müller W: Recurrent low-grade glioma: dedifferentiation and prospects of reoperation. in *Glioma: Principle and practice in neuro-oncology*. (Eds: Karim ABMF, Laws ER, Jr) Springer Verlag 1991, pp. 189-204.
3. Brandes A, Soesan M, Fiorentino MV: Medical treatment of high grade malignant gliomas in adults. An overview. *Anticancer Res* 11:719-728, 1991.
4. Chatel M, Lebrun C, Frenay M: Chemotherapy and immunotherapy in adult malignant gliomas. *Curr Opin Oncol* 5:464-473, 1993.
5. Coakham HB: Immunology of human brain tumors. *Eur J Cancer* 20:145-148, 1984.
6. Couldwell WT, Gopalakrishna R, Hinton DR, et al: Hypericin: a potential antiglioma therapy. *Neurosurgery* 35:705-709, 1994.
7. Ellison DW, Steart PV, Gatter KC, et al: Apoptosis in cerebral astrocytic tumours and its relationship to expression of the bcl-2 and p53 proteins. *Neuropathol Appl Neurobiol* 21:352-361, 1995.
8. EORTC Brain Tumour Group: Evaluation of CCNU, VM-26, plus CCNU, and procarbazine in supratentorial brain gliomas. *J Neurosurgery* 55:27-31, 1981.
9. EORTC Brain Tumour Group: Misonidazole in radiotherapy of supratentorial malignant gliomas in adult patients: A randomized double-blind study. *Eur J Cancer Clin Oncol* 19:39-42, 1983.
10. Fujiwara T, Matsumoto Y, Honma Y: A comparison of intraarterial carboplatin and ACNU for the treatment of gliomas. *Surg Neurol* 44:145-150, 1995.

11. Guthrie BL, Laws ER: Management of supratentorial low-grade gliomas. In: Glioma: Principle and practice in neuro-oncology. (Eds: Karim ABMF, Laws ER, Jr) Springer Verlag, 1991, pp. 75-92
12. Hall WA, Flores EP, Low WC: Antisense oligonucleotides for central nervous system tumors. *Neurosurgery* 38:376-383, 1996.
13. Hegarty TJ, Thornton AF, Diaz RF, et al: Intraarterial bromodeoxyuridine radiosensitization of malignant gliomas. *Int J Radiation Oncol Biol Phys* 19:421-428, 1990.
14. Hildebrand J, Sahmoud T, Mignolet F, et al: Adjuvant therapy with dibromodulcitol and BCNU increases survival of adults with malignant gliomas. *Neurology* 44: 1479-1483, 1994.
15. Kastan MB, Canman CE, Leonard CJ: P53, cell cycle control and apoptosis: Implications for cancer. *Cancer Metastasis Rev* 14:3-15, 1995.
16. Kleihues P, Burger PC, Scheithauer BW: World Health Organization. International histological classification of tumours. Histological typing of tumours of the central nervous system. 2nd ed. Springer, Berlin, Heidelberg, New York, Tokyo, 1993.
17. Kordek R, Biernat W, Alwasiak J, et al: p53 protein and epidermal growth factor receptor expression in human astrocytomas. *J Neuro-oncol* 26:11-16, 1995.
18. Louis DN, von Deimling A, Chung RY, et al: Comparative study of p53 gene and protein alterations in human astrocytic tumors. *J Neuropathol Exp Neurol* 52:31-38, 1993.
19. Lowe SW, Schmitt EM, Smith SW, et al: P53 is required for radiation-induced apoptosis in mouse thymocytes. *Nature* 362:847-849, 1993.
20. McCornack BM, Miller DC, Budzilovich GN, et al: Treatment and survival of low-grade astrocytoma in adult -1977-1988. *Neurosurgery* 31:636-642, 1992.
21. McKeran RO, Williams ES, Jones HT: The epidemiology of brain tumours. in: Primary malignant brain tumours (Ed: Thomas DGT) Edward Arnold London, Melbourne, Auckland, 1990 pp. 135-140.
22. Mikkelsen T, Cairncross JG, Cavenee WK: Genetics of the malignant progression of astrocytoma. *J Cell Biochem* 46:3-8, 1991.
23. Schiffer D, Cavalla P, Migheli A, et al: Apoptosis and cell proliferation in human neuroepithelial tumours. *Neurosci Lett* 195:81-84, 1995.
24. Schiffer D, Dutto A, Cavalla P, et al: Role of apoptosis in the prognosis of oligodendrogliomas. *Neurochem Int* 31:245-250, 1997.
25. Shaw P, Bovey R, Trady S, et al: Induction of apoptosis by wild-type p53 in a human colon tumor-derived cell line. *Proc Natl Acad Sci* 89:4495-4499, 1992.
26. Sidransky D, Mikkelsen T, Schwelheimer K, et al: Clonal expansion of p53 mutant cells is associated with brain tumour progression. *Nature* 355:846-847, 1992.
27. Sipos L, Wakabayashi T, Fazekas I, et al: Characterisation of human gliomas by a monoclonal antibody both on tissue culture and paraffin-embedded sections. *Neurol Res* 14:263-266, 1992.
28. Sipos L, Áfra D: Re-operations of anaplastic astrocytomas. *Acta Neurochir* 139:99-104, 1997.
29. Symonds H, Krall L, Remington L, et al: P53-dependent apoptosis suppresses tumor growth and progression in vivo. *Cell* 78:703-711, 1994.
30. Wakabayashi T, Yoshida J, Seo H, et al: Characterization of neuroectodermal antigen by a monoclonal antibody and its application in CSF diagnosis of human glioma. *J Neurosurg* 68:449-455, 1988.
31. Yoshida J, Wakabayashi T, Kito A, et al: Clinical application of monoclonal antibodies against glioma associated antigens. *Prog Exp Tumor Res* 30:44-56, 1987.