

CASE REPORT

An Unusual Case of Neurofibroma of the Thyroid Capsule

Antonio CIARDI, Irene PECORELLA, Giorgio TROMBETTA, Lorenzo MEMEO, Angeloluca De QUARTO,
Ugo Di TONDO

Department of Experimental Medicine and Pathology, University „La Sapienza”, Rome, Italy

A solitary neurofibroma arising from the thyroid capsule in a 64 year-old woman is reported. The tumor was adherent to the lower margin of the thyroid gland and extended into the anterior mediastinum. The unusual nature of the lesion, both its

relationship to the thyroid gland and to the occurrence of a neural tumor in the anterior mediastinum is discussed. (Pathology Oncology Research Vol 3, No 4, 293-295, 1997)

Key words: Visceral neurofibroma; peripheral nerve sheath tumors; thyroid capsule.

Introduction

Visceral neurofibromas are usually multiple, and occur as part of von Recklinghausen's syndrome, whilst the solitary form is uncommon and most often involves nerve plexuses in the form of a plexiform neurofibroma.¹ This paper describes a neurofibroma originated from the capsule of a thyroid gland, as discovered after surgery of a large thyroideal goiter with presumed extension into the superior-anterior mediastinum. Although peripheral nerve tumours do occur quite frequently in the head and neck region (45% of 303 patients in Gupta series),² an origin from the thyroid capsule has never been reported.

Case report

In November 1994, a 64 year-old woman was presented with a two-year history of dry cough, usually occurring at night. Physical examination revealed a homogeneously enlarged thyroid gland with a firm painless nodule in the left lobe, of which the lower margin extended substernally. No cervical lymph nodes were palpable. Thyroid hormone levels were within normal limits. Chest X-ray confirmed the presence of a well-circumscribed mass produc-

ing shift of the trachea to the right, but without evidence of infiltration of the surroundings. Ultrasound examination of the neck and thorax showed a markedly enlarged thyroid with a solid, hypoechoic mass originated from the lower aspect of the left lobe and extending substernally, up to the mediastinal vessels.

The clinical diagnosis of colloid goiter with presumed extension into the superior-anterior mediastinum was made. At surgery, the mediastinal nodule presented as a solid, hard, greyish mass and appeared to be adherent to the thyroid capsule. Neither the surrounding structures, nor any cervical nerve trunks were apparently involved. Because malignancy was suspected, the mass was removed along with the whole enlarged thyroid gland. Frozen sections were not required. The patient recovered well from surgery and is presently alive and well, with no neurological disturbances such as those due to recurrent laryngeal nerve injury.

Materials and Methods

Tissue specimens from both the tumor and thyroid gland were fixed in 10% buffered formalin and embedded in paraffin. Step sections were stained with haematoxylin-eosin, Mallory's trichrome, PAS, and alcian blue.

Immunohistochemical studies on paraffin-embedded material (peroxidase-antiperoxidase method and 3-amino-9-methyl-carbazole as chromogen substrate) were also performed using monoclonal antibodies against S-100 protein, vimentin intermediate filament (Ortho Diagnostic System),

Received: Oct 6, 1997; *accepted:* Nov 28, 1997

Correspondence: Antonio Ciardi, M.D., Dipartimento di Medicina, Sperimentale e Patologia, Policlinico Umberto I, Viale Regina Elena, 324, 00161 Roma, Italia; Tel. +39-6-49970842; fax: +39-6-4940896

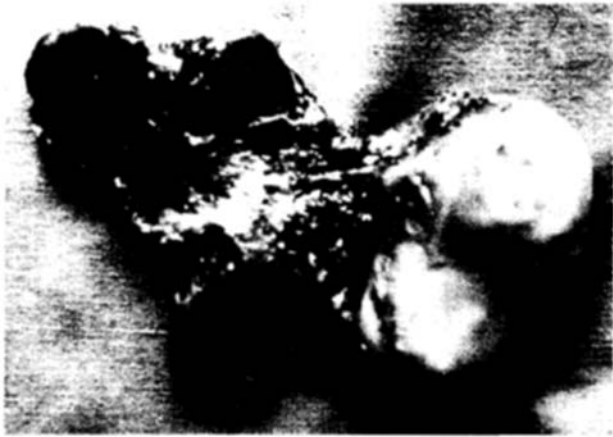


Figure 1. Back view of the thyroidectomy specimen, showing a bosselated nodule adherent to the lower aspect of the left lobe.

neurofilament protein (DAKO) and Leu 7 (Beckton Dickinson). The latter antibody cross-reacts with an antigenic determinant related to a myelin-associated glycoprotein.³

Pathology

Gross examination of the operative specimen revealed a moderately enlarged thyroid gland. A greyish-yellow, well-encapsulated, firm, oval mass measuring 5x4.8 x4 cm, with a smooth outer surface, was attached to the inferior and lateral margins of the left lobe (*Figure 1*). On section, multiple nodules, as well as areas of cystic degeneration and hemorrhage were observed in the thyroid gland, while the attached mass consisted of a grey-yellow tissue with moist, bosselated appearance. This appeared to bear no connection with the thyroid parenchyma itself, but was surrounded and demarcated from it by a 1 mm-thick fibrous tissue, in continuity with the thyroid capsule. Histology of the thyroid tissue confirmed the diagnosis of nodular colloid goi-



Figure 2. Positive immunoreaction with anti S-100 protein serum of twisted cells (PAP-AEC, 250x).

ter; the mediastinal mass, on the other hand was composed of areas with variably orientated interwoven bundles of elongated, wavy cells provided with fusiform, dark nuclei. Pleomorphism was minimal and only occasional mitoses were seen. The cellularity was low and palisading was not encountered. At the periphery, the tumour showed a loose texture with myxoid hypocellular areas similar to those seen in Antoni B areas of schwannomas; however, differently from the latter, these contained abundant mucoid Alcian blue positive matrix. Immunostaining with both S-100 (*Figure 2*) and vimentin revealed positivity in the tumor cells, although staining for vimentin was more diffuse, as compared to S-100. A few Leu-7 positive wavy cells were also observed. No neurofilament-positive structure was present within the tumor tissue. These findings were consistent with a neurofibroma of the thyroid capsule.

Discussion

Solitary neurofibroma is an uncommon benign tumor usually arising from the skin or subcutaneous tissue, and rarely affecting the viscera. To the best of our knowledge, the previously reported cases of neurofibroma and schwannoma of the thyroid area were entirely located within the thyroid gland^{4,7} or originated from the recurrent laryngeal nerve.^{2,8,9} It is possible that in the present case the tumor either originated from the thyroid capsule or developed extrinsically in the gland, causing atrophy of the peripheral rim of thyroid parenchyma. We believe the former possibility to be more acceptable since a nervous plexus, composed of autonomic nerves directed toward the parenchymal blood vessels and follicles is present within the thyroid capsule and may well have given origin to this nerve sheath tumour. The possibility that a mediastinal neurofibroma simply got close and adhered to the thyroid capsule is remote, because the nerve tumour was connected only to the thyroid gland and did not contain nerve segments emerging from its surface.

From an histological point of view, the present lesion appears to possess an admixture of findings characteristic of both neurofibroma and schwannoma, pointing to the common ancestry of the two tumors. Particularly, the presence of a complete fibrous capsule and the lack of nerve fibres within its context, would favour the diagnosis of schwannoma. However, although cutaneous neurofibroma does not possess a true capsule, as compared to schwannoma, visceral neurofibroma appears to be peculiar in this respect and particularly those arising in the mediastinum are often encapsulated.¹⁰ Also the presence of nerve fibers within the tumor does not always aid the distinction, as neurites can not always be identified in neurofibroma and are occasionally found in schwannoma, representing regenerating axons deriving from the parent nerve. Ackerman et al., who studied a small series of mediastinal neurofibromas,¹⁰ found that "...differences

between neurofibromas and neurilemmomas are more clear-cut in tumors of the peripheral nerves than in neurogenous tumors within the thorax". Overall, findings characteristic of neurofibroma prevailed and included the loose texture, the predominant intercellular component, the low cellularity, and the presence of a double cell population, composed of Schwann cells and fibroblasts.

In conclusion, cases such as this are now drawing attention to the possible occurrence of nerve sheath neoplasms in the thyroid region. Although nerve sheath tumors such as the one we have described are entirely benign, their location in the anterior mediastinum may allow them grow to a large size, and cause respiratory symptoms due to compression phenomena.

References

1. *Burger PC, Scheithauer BW, Vogel FS*: Surgical pathology of the nervous system and its coverings. Churchill Livingstone Inc, New York 1991, pp: 687-694.
2. *Gupta TKD, Brasfield RD, Strong EW, Hajdu SI*: Benign solitary schwannomas (neurilemmomas). *Cancer* 24:355-366, 1969.
3. *Perentes E, Rubinstein LJ*: Immunohistochemical recognition of human nerve sheath tumors by anti-Leu 7 (HNK-1) monoclonal antibody. *Acta Neuropathol* 68:319, 1985.
4. *Andrion A, Bellis D, Delsedime L, Bussolati G, Mazzucco G*: Leiomyoma and neurilemoma: report of two unusual non-epithelial tumours of the thyroid gland. *Virchows Archiv A Pathol Anat* 413:367-372, 1988.
5. *Capelli A, Guernelli L, Bertoni F*: Neurofibroma della tiroide. *Arch Chir Torac Cardiovasc* 32:23-27, 1975.
6. *Delaney WE, Fry KE*: Neurilemoma of the thyroid gland. *Ann Surg* 160:1014-1016, 1964.
7. *Goldstein J, Tovi F, Sidi J*: Primary schwannoma of the thyroid gland. *Int Surg* 67:433-434, 1982.
8. *Castrillo JM, Sarasa JL*: Formacion retroparotidica izquierda en una paciente intervenida de carcinoma papilifero tiroideo cuatro anos antes. *Revista Clinica Espanola* 186:91-95, 1990.
9. *Contant A, Acquaviva F*: Neurinome de la region thyroïdienne. Une observation. *Presse Med* 23:952, 1994.
10. *Ackerman LV, Taylor FH*: Neurogenous tumors within the thorax. *Cancer* 669-691, 1951.