

CASE REPORT

Mucinous Cystadenocarcinoma in Combination with Hemangiosarcoma in the Ovary

Anne Marie Bak JYLLING, Lars JØRGENSEN, Berit HØLUND

Department of Pathology, Odense University Hospital, Odense, Denmark

The ovary is the sixth most frequent site of cancer in women in Denmark with an incidence of approximately 600 cases per year. Carcinomas predominate whereas sarcomas are rare. We describe a case of the combination mucinous cystadenocarcinoma and hemangiosarcoma in a 37-year old woman, who had a right-sided oophorectomy because of a cyst. Clinically there was no suspicion

of malignancy. The macro- and microscopic findings are described as well as the immunohistochemical stainings performed to confirm the diagnosis. The case shows the importance of careful sampling at the macroscopic examination, especially from areas with a striking appearance. (Pathology Oncology Research Vol 5, No 4, 318–319, 1999)

Keywords: ovary, cystadenocarcinoma, mucinous, hemangiosarcoma

Introduction

The ovary is the sixth most frequent site of cancer in women in Denmark with an incidence of approximately 600 cases per year. Carcinomas predominate, whereas sarcomas are rare.^{1,2,5} Only a few cases of the combination of the two tumortypes in the ovary have been described.^{3,4,5}

Case report

A 37-year-old woman had a right-sided oophorectomy because of a cyst. Clinically there was no suspicion of malignancy.

Macroscopically the fallopian tube was normal. The ovary was cystically transformed, measuring 10x7x6 cm. The surface was smooth. On section there was a 3x3 cm multiloculated cystic area with a slightly slimy content. In some of the cysts scattered excrescences were seen on the inner surface. A small solid area with haemorrhage was also seen in relation to the cystic part (*Figure 1*).

Microscopically the cystic area showed a mucinous tumor of alternating differentiation: mucinous cystadeno-

ma, borderline and cystadenocarcinoma (*Fig. 2A*). Corresponding to the macroscopically described solid area with haemorrhage there was a malignant haemangiosarcoma. The tumor consisted of proliferating vessels with vacuolisation of the cytoplasm of the tumor cells around the vessel lumina (*Figure 2B and 3*).

In an area the two tumor types collided. To characterize the two tumor types a panel of immunohistochemical

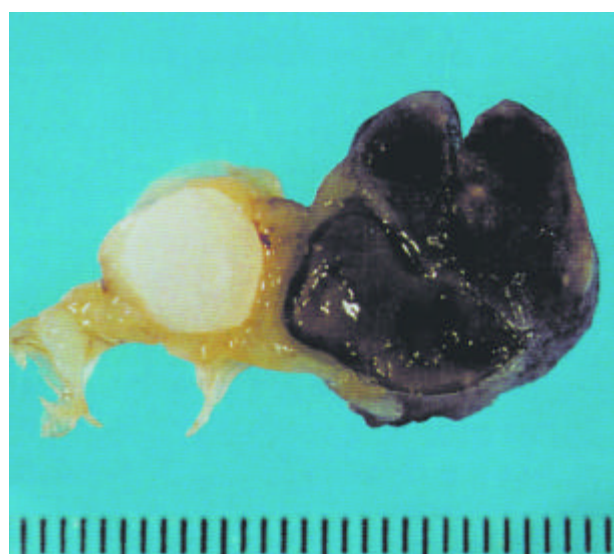

Figure 1. Macroscopic view of the ovarian tumor.

Received: July 5, 1999; *accepted* August 5, 1999

Correspondence: Dr. Anne Marie Bak JYLLING, Department of Pathology, Odense University Hospital, Winsloewparken 15, DK-5000 Odense C; Tel: +45 65 41 15 82; Fax: +45 66 12 27 83; E-mail: anne.marie.bak.jylling@ouh.dk

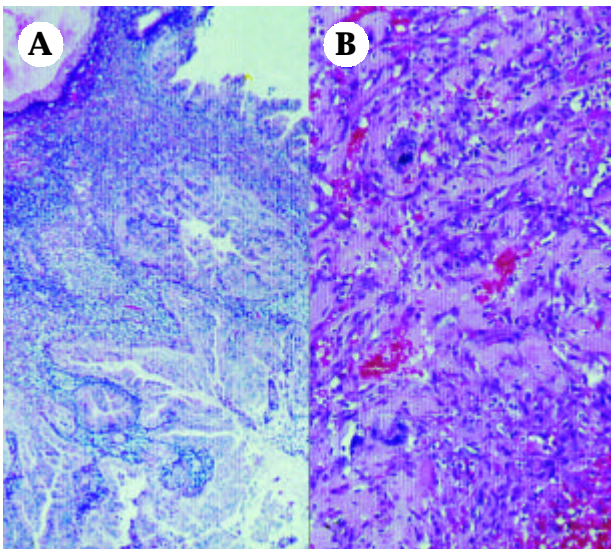


Figure 2A. Mucinous cystadenocarcinoma; **B:** Hemangiosarcoma.

stains was performed according to *Table 1*. The immunohistochemical stains support that the tumor is a mucinous cystadenocarcinoma in combination with a haemangiosarcoma and not a mucinous cystadenocarcinoma with an area of low differentiated carcinoma with proliferating vessels, as has been considered.

Discussion

This case shows the importance of careful sampling at the macroscopic examination, especially from areas with a striking appearance. It also shows the help, one can get from immunohistochemical stainings to confirm the diagnosis.

Table 1.

	HMV CK	LMV CK	CK 7	CK 20	EMA	VIM	F VIII	CD 34	UEA
Mucinous cystadeno-carcinoma	+	+	+	+	+	-	-	-	+
Haemangio-sarcoma	-	-	-	-	-	+	+	+	+

+ = positive, - = negative

HMV CK = High Molecular Weight Cytokeratine; LMW CK = Low Molecular Weight Cytokeratine; CK 7 = Cytokeratine 7; CK 20 = Cytokeratine 20; EMA = Epithelial Membrane Antigene; VIM = Vimentine; F VIII = Factor 8; CD 34 = CD 34; UEA = Ulex Europaeus Agglutinin

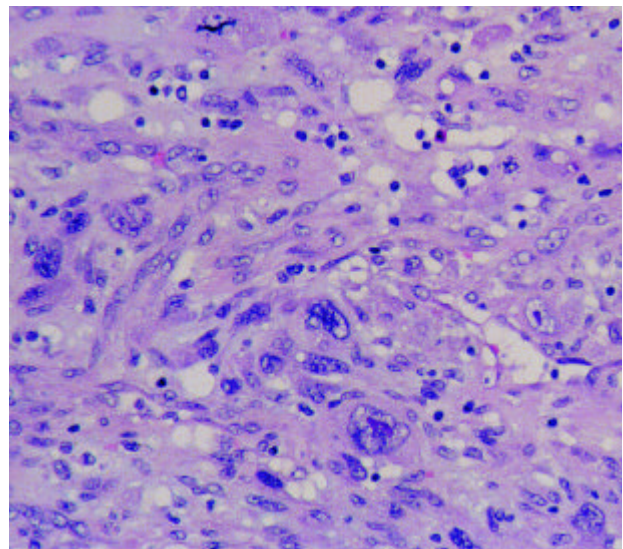


Figure 3. Hemangiosarcoma (higher magnification).

References

1. Ongkasuwan C, Taylor J, Tang C: Angiosarcomas of the Uterus and Ovary: Clinicopathologic report. *Cancer* 49:1469-1475, 1982.
2. Nucci M, Krausz T, Lifschitz-Mercer B: Angiosarcoma of the ovary. *Am J Surg Pathol* 22:620-630, 1998.
3. Prat J, Scully R: Sarcomas in ovarian mucinous tumors. *Cancer* 44:1327-1331, 1979.
4. Prat J, Scully R: Ovarian mucinous tumors with sarcoma-like mural nodules. *Cancer* 44:1332-1344, 1979.
5. Haines & Taylor: *Obstetrical and Gynaecological Pathology*. Churchill Livingstone, 1995.