

ARTICLE

Clinical Aspects of Alveolar Rhabdomyosarcoma with Translocation t(1;13)(p36;q14) and Hypotetraploidy

Bastian GUNAWAN,¹ Bernd GRANZEN,² Uma KELLER,² Gerd STEINAU,³ László FÜZESI,¹
Volker SCHUMPELICK,³ Rolf MERTENS²

¹Department of Pathology, Georg-August-University, Göttingen, Germany; and Departments of ²Pediatrics, and
³Surgery, Medical Faculty of the Technical University, Aachen, Germany

Although most cases of alveolar rhabdomyosarcoma (RMS) are characterized by the chromosomal translocation t(2;13)(q35;q14), several cases have been reported with a variant t(1;13)(p36;q14). We present the clinical, morphological and cytogenetic features of an alveolar RMS in a 4-year-old boy. Chromosomal analysis revealed a hypertriploid to

hypotetraploid karyotype with a t(1;13)(p36;q14) in all tumor cells. It appears that alveolar RMS with t(1;13) occurs in younger children and displays a higher incidence to upper and lower extremity than tumors with t(2;13). (Pathology Oncology Research Vol 5, No 3, 211–213, 1999)

Keywords: alveolar rhabdomyosarcoma, soft tissue, cytogenetics, chromosome

Introduction

Among the solid tumors of childhood, rhabdomyosarcoma (RMS) is the most common soft tissue sarcoma accounting for approximately 4–8% of childhood cancer.⁹ RMS is generally classified into two main categories, embryonal, including the botryoid and the spindle cell variant, and alveolar, including the classical and the more recently recognized solid variant. According to the International Classification of Rhabdomyosarcoma, alveolar histology is associated with a poorer prognosis, even when alveolar formations are not prominent.¹⁴ Cytogenetically, alveolar RMS is characterized by two consistent chromosomal translocations, the common t(2;13)(q35;q14),^{7,17,18} and the variant t(1;13)(p36;q14),^{6,2,3,19} resulting in the formation of the PAX3-FKHR and PAX7-FKHR fusion genes, respectively.^{16,4} Correlation with clinicopathologic data suggests that these two genetic subgroups identify distinct clinical phenotypes.¹¹

Translocation t(2;13) may distinguish a group of patients with older age, truncal primary tumors, and advanced

stage disease,⁸ while RMS with t(1;13) have been reported in younger patients presenting with tumors at extremity sites.^{6,2,3,19} As tumor-cell ploidy is concerned, diploidy is considered to be a common feature in both alveolar and embryonal tumors, while tetraploidy is more commonly associated with alveolar, and intermediate levels of hyperdiploidy with embryonal histology.¹⁵

We report a case of an alveolar RMS with t(1;13)(p36;q14) and hypertriploid to hypotetraploid chromosome numbers.

Case report

A 4-year-old boy presented with a mass of up to 4 cm in diameter in his right upper arm. Histopathologic evaluation of the resected lesion revealed a diagnosis of alveolar RMS. Clinical staging neither showed any metastases nor gross residual tumor. As resection had not been radical according to surgical guidelines, combination chemotherapy according to the Cooperative German Soft Tissue Sarcoma Study CWS-91 was initiated,¹³ followed by a second look operation with compartment resection of the brachialis muscle and dissection of the right axilla, and local radiotherapy with a total dose of 30 Gy. Chemotherapy was completed 7 months after the initial diagnosis. Five months later, the patient presented with recurrent RMS in his right axilla. Relapse treatment consisted of

Received: April 30, 1999; accepted: July 3, 1999

Correspondence: Rolf MERTENS, M.D.; Department of Pediatrics, Medical Faculty, RWTH, Pauwelsstr. 30, D-52057 Aachen, Germany; Tel:+49/241/80-89-941, fax: +49/241/88-88-492

Table 1. Cases of alveolar RMS with t(1;13)(p36;q14)

Case	Age/Sex/Site	Karyotype	Reference
1	2 yr/M/Thigh	46-48,XY,t(1;13)(p36.1;q14),+2,+6,der(14)t(1;14)(q11;p11)[cp15]/84-91,idemx2[cp5]	[6] ¹
2	2 yr/F/Leg	91,XXXX,t(1;13)(p36;q14)x2,-18[12]	[6] ¹
3	11 mo/M/Thigh	46,XY,t(1;13)(p36;q14)[23]/46,XY[4]	[2]
4	5 yr/M/Buttock	46,XY,der(1)(1qter-1q32::1p36-1q32::13q14-13qter),der(13)(13pter13q14::1p361pter)[5]/46,XY[20]	[3] ²
5	8 yr/M/Foot	92,XXYY,t(1;13)(p36;q14),del(6)(q14),dmin[?]/46,XY[?]	[19] ³
6	4 yr/M/Arm	73-82<4n>,YY,t(X;21)(q21;q21)x2,t(1;13)(p36;q14),der(1)t(1;13)(p36;q14),-3,-6,t(6;17)(p25;q12),der(6)t(6;17)(p25;q12),add(7)(p22)x2,-9,-10,-11,-13,-14,-15,-17,-17,-18,-21[cp25]	present case

¹ Earlier ISCN nomenclatures have been converted into the current ISCN 1995 form.

² No karyotype given in the original reference; karyotype has been constructed from the text in the paper.

³ Number of cells not indicated in the original reference.

surgical excision with dissection of the remaining fat and lymph nodes from the axilla, high-dose chemotherapy according to the German CESS/CWS REZ 91 trial with autologous bone marrow transplantation, and local radiotherapy with 48 Gy.¹² This treatment strategy induced a stable remission and 53 months after his relapse the patient is alive and free of disease.

Pathologic study

The tumor consisted of clusters of densely packed, small round cells divided by fibrous septae. Alveolar formations were focally seen. Most of the tumor cells were small to moderate in size with little cytoplasm, containing round basophilic chromatin-dense nuclei. Mitoses were frequent.

Occasionally, typical rhabdomyoblasts with abundant eosinophilic cytoplasm and large eccentric nuclei were seen. Periodic acid-Schiff (PAS)-staining was weakly positive.

Cytogenetic study

Fresh, sterile tumor tissue was processed immediately for short-term cell culture and cytogenetic analysis according to standard procedures. Chromosome preparations were performed within the first week of the primary culture using standard GTG banding techniques (Figure 1). Twenty-five metaphases were fully karyotyped according to the

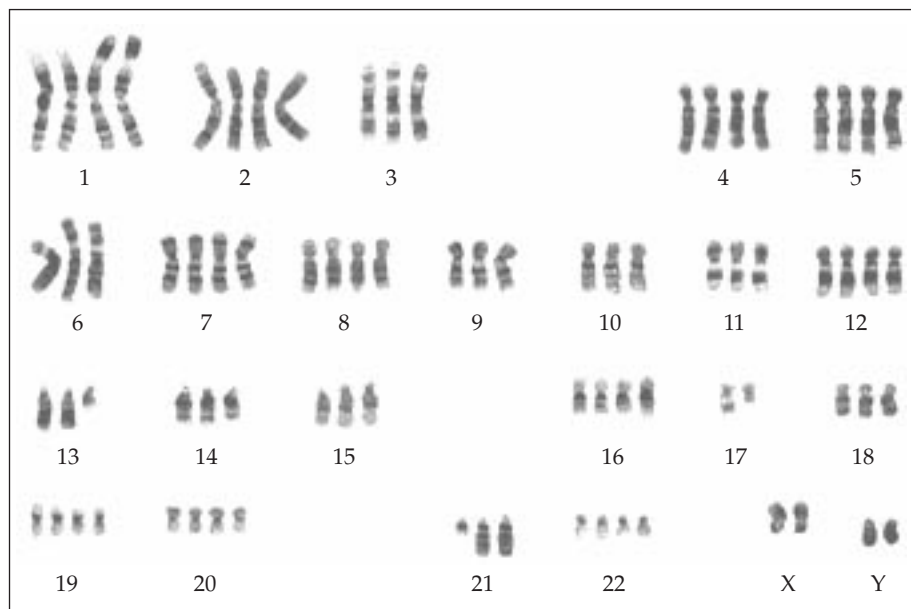


Figure 1. Representative G-banded karyotype demonstrating a modal chromosome number of 80 and t(1;13)(p36;q14).

international nomenclature ISCN (1995).¹⁰ The composite karyotype was:

73-82<4n>,YY,t(X;21)(q21;q21)x2,t(1;13)(p36;q14),der(1)t(1;13)(p36;q14),-3,-6,t(6;17)(p25;q12),der(6)t(6;17)(p25;q12),add(7)(p22)x2,-9,-10,-11,-13,-14,-15,-17,-17,-18,-21[cp25]

Discussion

The chromosomal translocations t(2;13) and t(1;13) and the associated PAX3-FKHR and PAX7-FKHR fusion genes are valuable diagnostic markers in the differential diagnosis of small round cell tumors of childhood. Recently, however, there is increasing evidence that these genetic markers may also have prognostic implications. Even though the fusion transcripts created by the two translocations are similar, the genetic patterns appear to be associated with distinct clinical phenotypes. In a large series of patients with t(2;13)-positive RMS, Douglass et al. identified clinical features, including older age, primary tumor of the trunk, metastatic disease, and aggressive behaviour.⁸ In the initial case reports of six patients with variant t(1;13) or PAX7-FKHR fusion genes, respectively, the patients were not older than 8 years and presented with tumors of the lower extremity (Table 1.).^{6,2,3,19,1} In a recent and most largest series Kelly et al. not only identified distinct clinical features, including younger age, tumor of the extremity and localized disease, but also a trend toward better overall survival in patients with PAX7-FKHR-positive tumors.¹¹ These findings suggest that the two genetic patterns predict distinct clinical phenotypes with prognostic implication.

As regards tumor-cell ploidy, all cytogenetically analyzed cases of t(1;13)-bearing RMS have been reported to be near-diploid or -tetraploid, respectively.^{6,2,3,19} The diagnostic and prognostic implication of tumor-cell ploidy in pediatric RMS has been investigated in several studies.^{15,5} Initially, hyperdiploidy was found to be correlated with more favorable clinical outcomes than cases with diploid or tetraploid DNA content. However, it appears that ploidy is at least partly related to histologic subtype, and it is not clear whether ploidy is an independent prognostic factor.

The present case of a t(1;13)-positive RMS with hypertriploid to hypotetraploid chromosome numbers shows a favorable clinical course. Although the patient developed a relapse, a stable second remission was achieved and the patient has since been free of disease. The abnormal ploidy and the complex karyotype of the analysed tumor may represent secondary effects after chemotherapy. With the development of molecular assays using RT-PCR methods to detect PAX7-FKHR fusion transcripts in formalin-fixed specimens,¹ future studies may clarify the prognostic significance of tumor-cell ploidy in this distinct subgroup of alveolar RMS.

References

1. Anderson J, Renshaw J, McManus A, et al: Amplification of the t(2;13) and t(1;13) translocations of alveolar rhabdomyosarcoma in small formalin-fixed biopsies using a modified reverse transcriptase polymerase chain reaction. *Am J Pathol* 150:477-482, 1997.
2. Biegel JA, Meek RS, Parmiter AH, et al: Chromosomal translocation t(1;13)(p36;q14) in a case of rhabdomyosarcoma. *Genes Chromosomes Cancer* 3:483-484, 1991.
3. Dal Cin P, Brock P, Aly MS, et al: A variant (2;13) translocation in rhabdomyosarcoma. *Cancer Genet Cytogenet* 55:191-195, 1991.
4. Davis RJ, D'Cruz CM, Lovell MA, et al: Fusion of PAX7 to FKHR by the variant t(1;13)(p36;q14) translocation in alveolar rhabdomyosarcoma. *Cancer Res* 54:2869-2872, 1994.
5. De Zen L, Sommaggio A, d'Amore ESG, et al: Clinical relevance of DNA ploidy and proliferative activity in childhood rhabdomyosarcoma: A retrospective analysis of patients enrolled onto the Italian Cooperative Rhabdomyosarcoma Study RMS88. *J Clin Oncol* 15:1198-1205, 1997.
6. Douglass EC, Rowe ST, Valentine M, et al: Variant translocations of chromosome 13 in alveolar rhabdomyosarcoma. *Genes Chromosomes Cancer* 3:480-482, 1991.
7. Douglass EC, Valentine M, Etcubanas E, et al: A specific chromosomal abnormality in rhabdomyosarcoma. *Cytogenet Cell Genet* 45:148-155, 1987.
8. Douglass EC, Shapiro DN, Valentine M, et al: Alveolar Rhabdomyosarcoma with the t(2;13): cytogenetic findings and clinicopathologic correlations. *Med Pediatr Oncol* 21:83-87, 1993.
9. Enzinger FM, Weiss S: *Soft Tissue Tumors*. Third edition. St. Louis: Mosby-Year Book, Inc., 1995.
10. ISCN (1995): *An International System for Human Cytogenetic Nomenclature*, Mitelman F (ed). S. Karger, Basel, 1995.
11. Kelly KM, Womer RB, Sorensen PHB, et al: Common and variant gene fusions predict distinct clinical phenotypes in rhabdomyosarcoma. *J Clin Oncol* 15:1831-1836, 1997.
12. Klingebiel T, Perl U, Hess CF, et al: Treatment of children with relapsed soft tissue sarcoma: report of the German CESS/CWS REZ 91 trial. *Med Pediatr Oncol* 30:269-275, 1998.
13. Multizentrische Therapiestudie zur Behandlung von Kindern und Jugendlichen mit Weichteilsarkomen, Cooperative Weichteilsarkomstudie CWS-91, Fassung vom 10. Mai 1991.
14. Newton WA Jr, Gehan EA, Webber BL, et al: Classification of rhabdomyosarcomas and related sarcomas. Pathologic aspects and proposal for a new classification – an Intergroup Rhabdomyosarcoma Study. *Cancer* 76:1073-1085, 1995.
15. Shapiro DN, Parham DM, Douglass EC, et al: Relationship of tumor cell ploidy to histologic subtype and treatment outcome in children and adolescents with unresectable rhabdomyosarcoma. *J Clin Oncol* 9:159-166, 1991.
16. Shapiro DN, Sublett JE, Baitao LI, et al: Fusion of PAX3 to a member of the forkhead family of transcription factors in human alveolar rhabdomyosarcoma. *Cancer Res*, 53:5108-5112, 1993.
17. Turc-Carel C, Lizard-Nacol S, Justrabo E, et al: Consistent chromosomal translocation in alveolar rhabdomyosarcoma. *Cancer Genet Cytogenet* 19:361-362, 1986.
18. Wang-Wuu S, Soukup S, Ballard E, et al: Chromosomal analysis of sixteen human rhabdomyosarcomas. *Cancer Res* 48:983-987, 1988.
19. Whang-Peng J, Knutsen T, Theil K, et al: Cytogenetic studies in subgroups of rhabdomyosarcoma. *Genes Chromosomes Cancer* 5: 299-310, 1992.