

## CASE REPORT

## Bronchial Capillary Hemangioma in Adults

János STRAUSZ, Ibolya SOLTÉSZ

Korányi National Institute of Pulmonology, Budapest, Hungary

Two cases with capillary hemangioma of the trachea and the left upper lobe bronchus are presented. The adult patients were referred to the hospital because of hemoptysis and cough. The chest radiographs were normal in both cases. The bronchoscopic examination revealed circumscribed lesions with a capillarized surface protruding into the lumen of the trachea and the left upper lobe bronchus,

**Keywords:** hemangioma, bronchus, hemoptysis

respectively. The lesions were excised in toto with flexible bronchoscopic forceps. The specimens contained typical capillary hemangiomas without any signs of malignancy. Capillary hemangioma in the bronchial tree is an extremely rare benign lesion in adults. Nevertheless, it should be considered as a possible cause of hemoptysis and cough. (Pathology Oncology Research Vol 5, No 3, 233–234, 1999)

### Introduction

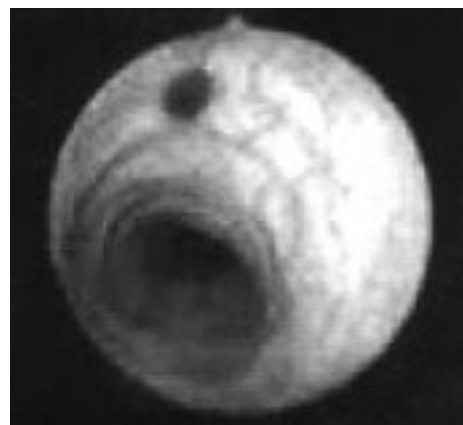Hemangiomas occur frequently in childhood. There are generally multilocalized and the upper respiratory tract is often involved. Capillary hemangioma of the lower respiratory tract is a very rare lesion and occurs mostly in infants.<sup>2,5</sup> Two cases with this unique alteration in the trachea and left upper lobe bronchus are presented which were detected while searching for the causes of hemoptysis and cough. The hemangiomas were successfully treated with the bronchoscope.

### Case Reports

#### Case 1

A 55-year-old male heavy smoker patient was admitted to hospital with emergency. He complained that after a heavy attack of coughing blood appeared in his sputum. Chest roentgenogram was negative and neither clinical signs nor blood chemistry showed a possible cause of hemoptysis. Flexible bronchoscopy performed under local anesthesia revealed a reddish color lesion with a

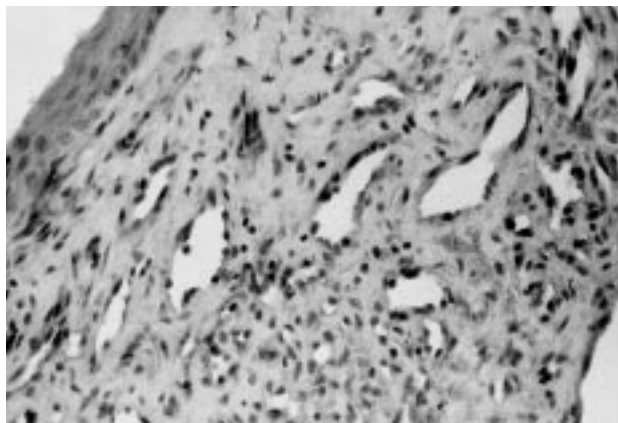
capillarized surface on the ventral wall of the middle trachea 2x2 mm in size (*Figure 1*). The lesion was excised en block with biopsy forceps without significant bleeding. The histology revealed (*Figure 2*) a fine network of thin-walled vessels. The endothelial cells (factor VIII antigen positive) showed usual shape and size with normal nuclei. Metaplastic squamous cells covered the lesion. Three months after the treatment the control bronchoscopy showed normal mucosa at the site of the excised lesion.



**Figure 1.** Bronchoscopic feature of the hemangioma in the trachea.

Received: March 25, 1999; accepted: June 22, 1999

Correspondence: János STRAUSZ, M.D., Korányi National Institute of Pulmonology, H-1529, Pihenő u. 1, Budapest, Hungary; Tel: +36 1 200 2683; E-mail: str12196@helka.iif.hu



**Figure 2.** The histology shows squamous cell metaplasia, accumulated erythrocytes and irregular network of capillary in the submucosa. (H&E, x300).

### Case 2

A 70-year-old housewife was admitted to hospital because of chronic cough. Chest radiograph and lung function test did not show any alteration. Bronchoscopy revealed signs of chronic bronchitis, and on the carina between lingula-, and S3 there was bronchus a red smooth surface lesion 5x4 mm in size. This lesion looked like a small vesicle filled with blood. Forceps biopsy was performed without significant bleeding. Histologic examination showed squamous cell metaplasia of the respiratory epithelium. The subepithelial layer was filled with blood cells and in the submucosa there was a circumscribed area consisting of delicate network of capillaries. The endothelial cells showed normal shape, and had large, regular nuclei protruding into the capillary spaces. Factor VIII antigen was positive. There were no signs of malignant transformation. After the diagnosis of capillary hemangioma, the base of the lesion was coagulated with Nd-YAG laser. The patient's complaint discontinued promptly after the bronchoscopic intervention. Three months later the control bronchoscopy revealed normal mucosal surface at the site of the former lesion.

### Discussion

In infants hemangioma can be distinguished from other vascular malformation by clinical course and by pathomorphological characteristics. This tumor appears by the sixth month of life, most of them occur in the subglottic area, and they spontaneously regress by the seventh year of life. This tumor commonly causes dyspnoe and/or stridor and is treated by surgical resection.<sup>1,4</sup> In the literature, we found only a single similar capillary hemangioma in bronchial tree in adults: a pedunculated lesion was described in

a 67-year-old woman obstructed the left lower lobe bronchus.<sup>3</sup> This lesion caused radiological signs (left lower lobe atelectasis), and it was removed at bronchoscopy. According to the author of this case, the bronchial capillary hemangioma differs from hemangioma derived from alveolar capillaries not only by the location and clinical signs, but also by size, which is the consequence of the differing time of the presentation. This type of hemangioma consists of matured endothelial cells forming a circumscribed fine network of thin-walled vessels. They did not show any signs of malignant transformation.

In our cases the lesions were discovered whilst searching for the causes of non-characteristic clinical symptoms (cough and hemoptysis), which discontinued promptly after the bronchoscopic interventions. The specimens showed similar histologic characteristics to the above-mentioned published bronchial hemangioma. However, macroscopically they were not pedunculated, but they had a flattened shape and discrete size, and therefore they did not cause any obstruction of the airways. The normal bronchial ciliated epithelium over both hemangiomas had transformed into squamous cells as the sign of metaplasia.

In adults, the most frequent causes of cough and hemoptysis are malignant tumors, infectious diseases (pneumonia, chronic bronchitis, tuberculosis), cardiovascular disorders and other inflammatory diseases. In cases with negative chest radiograph, bronchoscopy is often indicated despite the fact that this intervention rarely clarifies the cause of these symptoms.<sup>6</sup> However, negative bronchoscopic findings could also provide an important differential-diagnostic advantage in the management of the patient.

We report two cases of adult capillary hemangioma of the bronchial tree, which were discovered whilst searching for the causes of non-characteristic respiratory symptoms. These exceptionally rare lesions were successfully treated by bronchoscopy.

### References

1. Dail DH: Uncommon Tumors. In: Dail DH, Hammar SP, Eds. Pulmonary Pathology. Springer-Verlag, New York, 847-972, 1988.
2. Franks R, Rothera M: Cardiopulmonary bypass for resection of low tracheal haemangioma. Arch Dis Child 65:630-632, 1990.
3. Harding IR, Williams J, Seal RM: Pedunculated capillary haemangioma of the bronchus. Br J Dis Chest 72:336-342, 1978.
4. Mori S: Sclerosing hemangioma of the lung. Dis Chest 54:71-74, 1968.
5. Paul KP, Borner C, Muller KM, et al: Capillary hemangioma of the right main bronchus treated by sleeve resection in infancy. Am Rev Respir Dis 143:876-879, 1991.
6. Prakash UBS, Freitag L: Hemoptysis and Bronchoscopy-Induced Hemorrhage. In: Prakash UBS, Ed. Bronchoscopy. Raven Press New York. 227-251, 1994.