

Spontaneous Remission in Localized Diffuse Large B-cell Lymphoma

László Tamás · Eszter Sári · Gábor Répássy ·
Péter Szabó · Enikő Bagdi · László Krenács ·
Judit Demeter

Received: 15 January 2011 / Accepted: 6 February 2011 / Published online: 10 June 2011
© Arányi Lajos Foundation 2011

Abstract Diffuse large B-cell lymphoma (DLBCL) is an aggressive neoplastic disease of the lymphatic system, the activated B-cell type of this disease is likely to have a substantially worse prognosis. In this study, we report the favorable outcome of the activated B-cell type of DLBCL, though untreated, 7 years after diagnosis. In 2003, DLBCL localized to the root of tongue was found in the patient complaining of dysphonia and a pharyngeal globus perception but the patient did not agree to get any active hematological treatment. During the following years, the patient did not have any complaints. At the otorhinolaryngological control examination, in 2010, she was complaint-free, had normal laboratory parameters. Moreover a PET-

CT scan did not reveal metabolic activity relating to malignancy. The extraordinary disease process can be explained by the spontaneous regression of the activated B-cell type DLBCL. Spontaneous regression of oral lymphoma has been published only exceptionally. To our knowledge, no report of spontaneous regression of activated B-cell type DLBCL has been reported.

Keywords Diffuse large B-cell lymphoma · Spontaneous remission · Activated B-cell type DLBCL · Root of tongue · Untreated lymphoma

Abbreviations

DLBCL	Diffuse large B-cell lymphoma
IPI	International Prognostic Index
aaIPI	Age adjusted International Prognostic Index
GCB	Germinal center-B-cell type
ABC	Activated B-cell type
Bcl 2	B-cell lymphoma 2
MUM1	Multiple myeloma oncogene 1
Cytokeratin A1-A3	Pankeratin monoclonal antibody
HGAL	Human Germinal Center Associated Lymphoma Protein
EBV	Ebstein-Barr-virus
EBV-LMP1	EBV-Latent membrane protein 1
CBC	complete blood count...
LDH	Lactate dehydrogenase
ORL	Otorhinolaryngeal
CT	Computer Tomography
PET	Positron Emission Tomography
FDG	Fluoro-desoxyglucose
NHL	Non-Hodgkin's lymphoma
IL-4	Interleukin -4

L. Tamás (✉)
Department of Oto-Rhino-Laryngology, Head and Neck Surgery,
Jahn Ferenc Hospital,
Köves u. 1.,
1204 Budapest, Hungary
e-mail: tamlaci@freemail.hu

E. Sári · J. Demeter
1st Department of Internal Medicine—Division of Hematology,
Semmelweis University,
Budapest, Hungary

G. Répássy
Department of Oto-Rhino-Laryngology, Head and Neck Surgery,
Semmelweis University,
Budapest, Hungary

P. Szabó
PET-CT Medical Diagnostic Ltd.,
Budapest, Hungary

E. Bagdi · L. Krenács
Laboratory of Tumor Pathology and Molecular Diagnostics
Szeged,
Szeged, Hungary

Introduction

Diffuse large B-cell lymphoma (DLBCL) is an aggressive neoplastic disease of the lymphatic system. The disease is usually lethal within a period of half a year to 2 years if left untreated. The prognosis of the disease is characterized best by the International Prognostic Index (IPI). The factors determining IPI are: age; LDH level; performance status; clinical stage of the disease, presence or absence of extranodal disease. In the case of the age-adjusted IPI (aaIPI) differentiated evaluation of patients under the age of 60 and of those above the age of 60 is carried out considering 3 factors: clinical stage; LDH level and performance status. The morphological subtypes of the disease are of established prognostic importance (i.e. immunoblastic and plasmoblastic morphologies have been associated with poor outcome). Nevertheless, it was a great step forward when genetic features were recognized to contribute to the prognostic discrimination of DLBCL subtypes. According to the gene expression studies, two types of the disease can be distinguished: a germinal center B-cell like (GCB) type and an activated B-cell type (ABC) [1]. The activated B-cell type form of DLBCL was shown to have a substantially worse prognosis [2]. The next step of huge importance was that the molecular classification of DLBCL could be proven by immunohistochemistry. The GCB and non-GCB phenotypes can reliably be differentiated by means of using certain immunohistochemical markers [3]. The survival chances of both types of the disease have greatly improved since the chemotherapy was combined with molecularly targeted therapy, using anti-CD20 monoclonal antibody.

In this study, we report the favorable clinical course of a female patient diagnosed with the activated phenotype of DLBCL in 2003. Though the patient refused to accept treatment or regular haematological follow-up, nevertheless 7 years later she has neither symptoms nor complaints. As to our knowledge, no cases of spontaneous regression of activated B-cell type DLBCL have been reported until now.

Case Report

A 66-year-old woman in good general health presented at our outpatient clinic in 2003 with a 3-week history of dysphonia and a pharyngeal globus perception. Her medical history revealed hysterectomy due to leiomyoma, as well as total adnexectomy, and the histology proved endometrioid neoplasia in the ovaries. The patient did not take any medication on a regular basis.

Physical examination revealed a swelling between the left vallecula and the root of tongue measuring 2 × 1 cm, but no lymphadenopathy in the region of the head and neck or

anywhere else was detected, neither was hepatosplenomegaly present. The laboratory test results showed a moderate elevation of the red blood cell sedimentation rate with normal peripheral cell numbers. Histological assessment of the biopsy material taken from the swelling showed, in addition to some lymphatic tissues with regular germinal centers, malignant tumor tissue. The tumor cells had prominent eosinophilic nucleoli, their nuclei were light, variously shaped and surrounded by narrow rims of eosinophilic cytoplasm. Several, mainly atypical cell divisions were visible. Immunohistochemistry showed these tumor cells to be negative with cytokeratin-, kappa-, lambda-, CD15-, S100-, cytokeratin AE1-AE3, melan -A, CD30 antibodies. However, the tumor cells were positive with B-cell markers and negative with T-cell markers. The diagnosis of high grade B-cell lymphoma was made. Staging examinations including chest, abdominal and pelvic CT scans were performed to gain information about the lymph node status and the penetration of the tumor into other organs. The patient did not yield consent to bone marrow biopsy and did not present herself to the follow-up examination within the next 6 months. The CT scan did not show any pathologic sized lymph nodes, only a mild hepatosplenomegaly was identified. Six months later the complaint-free patient underwent a control CT-scan of the neck, chest, abdomen and pelvis but, according to these tests, lymphadenopathy still was not present.

One year after the diagnosis, in 2004 the patient was still asymptomatic, physical examination did not reveal any morbidity. Laboratory results including CBC and LDH were within normal range. The control CT scan of the neck and chest did not reveal lymphadenopathy. The negative status was confirmed by an otorhinolaryngological examination, and there were no signs of local progression.

Considering that this indolent behavior is not typical for a DLBCL, we sent a sample from the original biopsy material taken from the root of the tongue to a hematopathological laboratory for histological revision. The second look examination defined the disease as an immunoblastic variant of the DLBCL with activated B-cell like immunophenotype. The tumor cells showed a weak focal positivity for CD20, CD38, a relatively homogenous cytoplasmic positivity for CD79a and an extensive positivity for MUM-1, BCL-2 and cytoplasmic immunoglobulin light chain kappa, but negativity for CD5, EBV-LMP1, BCL-6 and CD10 (Fig. 1).

The patient did not show up for further hematological control examinations, in spite of calls and telephone-interviews. In April 2010 at the otorhinolaryngological control examination, she was complaint-free, and had negative laboratory parameters (normal LDH and beta-2-microglobuline level) as well as negative ORL status. Nevertheless, the control CT scan of the neck revealed a

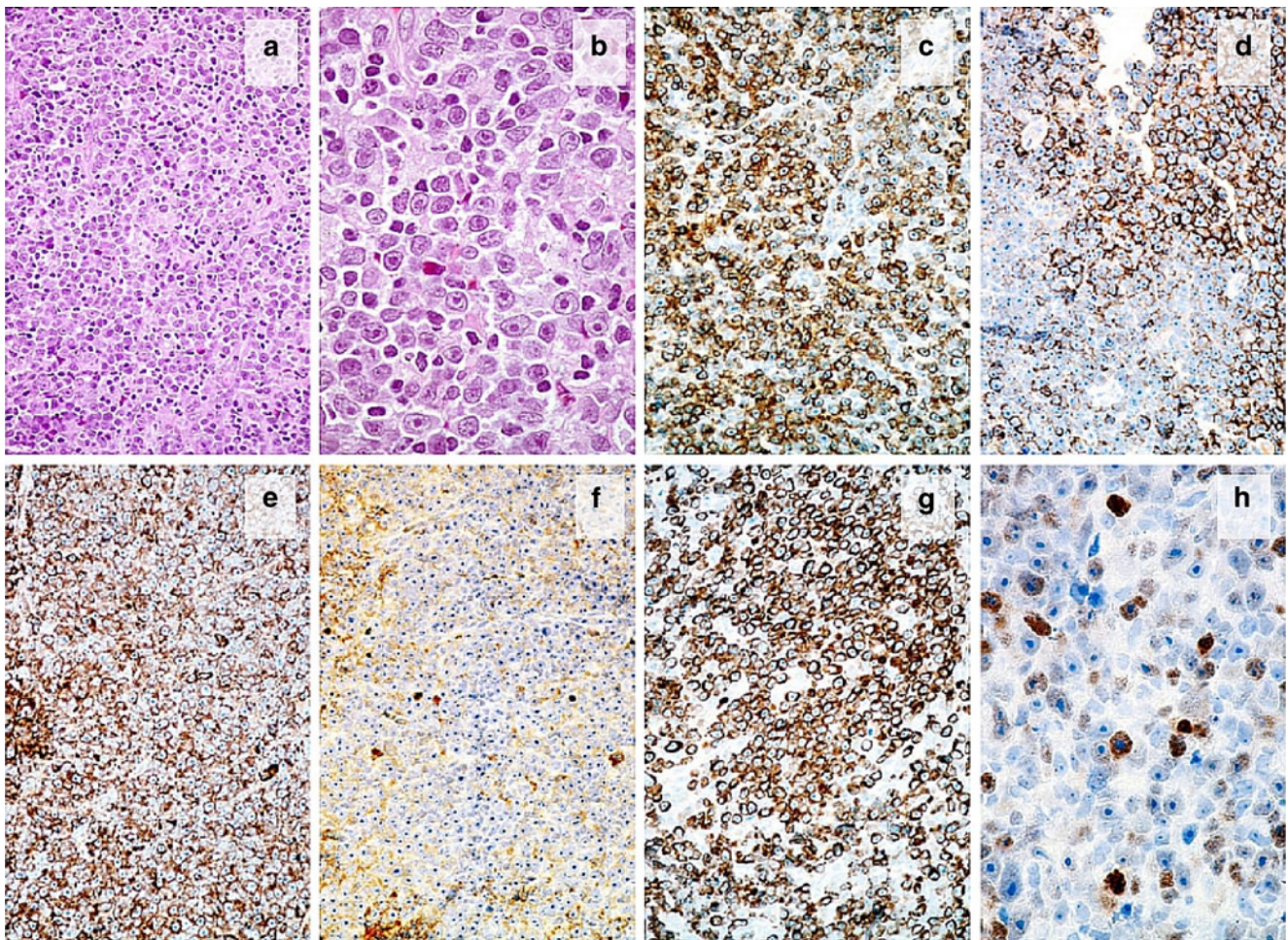


Fig. 1 Histopathology and immunophenotype of the tongue tumor. **a** Lymphomatous infiltrate in the root of tongue (H&E, original magnification $\times 100$). **b** Large lymphoma cells reveal “immunoblastic” cytomorphology (H&E, original magnification $\times 400$). Immunophenotype of the tumor cells: CD79a + **c**, CD20 partially + **d**, kappa + **e**, lambda- **f**, Bcl-2+ **g**, MUM1 partially + **h** (immunoperoxidase method, original magnifications C-G $\times 100$, and H $\times 400$). A diffuse lymphomatous tissue proliferation is present in the biopsy sample

fine contrast agent concentrating mass in the root of the tongue and a pathological sized lymph node in the mediastinum. To determine whether the contrast agent concentrating mass is a residuum of the former operation or a local recurrence we performed a PET-CT scan with no pathological FDG-accumulation at the root of the tongue while the mediastinal nodes were found to be reactive (Fig. 2).

In summary, due to the patient’s will we became passive witnesses of the spontaneous regression of an activated B-cell type DLBCL.

Discussion

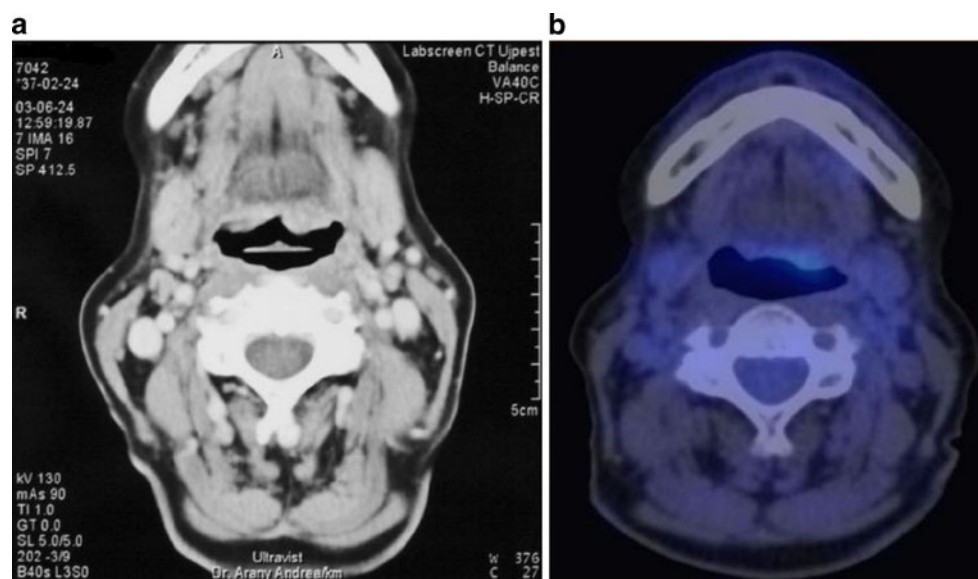
We designate spontaneous regression the partial or total diminution of a malignant tumor without any treatment⁴.

taken from the tumor of the tongue root, the atypical cells show an immunoblastic morphology with prominent nucleoli, with relatively transparent nuclei and with visible cytoplasmatic rim. Immunohistochemical tests showed a weak focal positivity for CD20, CD38, a relatively homogenous cytoplasmic positivity for CD79a, extensive positivity for MUM-1, BCL-2 and cytoplasmic immunoglobulin light chain kappa

However, it is important to mention that, unfortunately, most of the patients relapse after a while, that is, in most of the cases there is no definitive recovery of the malignant neoplasm. Spontaneous regression has been observed in several cases of hypernephroma, neuroblastoma, malignant melanoma, breast tumor and leukaemia/lymphoma [5]. Although mechanisms of tumor regression differ in various tumors, we summarize the main mechanisms of tumor regression in the Table 1.

Spontaneous regression in lymphomas can be attributed to bacterial or viral infection as well as enhanced immune response [6] of the host against the tumor [7–9]. The status of the host’s immune system has a great role in the spontaneous remission during of non-Hodgkin’s lymphomas. This is exemplified by the observations made during the progression of Epstein-Barr-virus-associated lymphoma

Fig. 2 **a** In the background of the patient's dysphonia, at the border of the left vallecula and the root of the tongue, a definite mass of 2x1 cm diameter has been identified without associated lymphadenopathy (left picture, contrast CT-image). **b** The PET-CT scan made 7 years later, did not reveal any pathological FDG-uptake in this region (right picture)



in patients after organ transplantation or AIDS-patients. While the EBV-associated lymphoma spontaneously diminishes after having finished the immunosuppressive therapy, in patients with AIDS the immunodeficient status is irreversible and the EBV-associated lymphoma does not regress spontaneously [7].

As opposed to low-grade lymphomas, where the occurrence of spontaneous regression is as high as about 5–15%, in cases of aggressive lymphomas spontaneous regression is extremely rare (in a retrospective study involving 69 cases with aggressive lymphoma a proportion of 2% has been published, Gattiker [8]). In clinical practice, chemotherapy or immunochemotherapy is started immediately after diagnosis of malignant lymphoma and staging procedures, thus nowadays, the rate of spontaneous regressions of NHLs is unknown, only case reports give information about them. Abe et al. evaluated 15 cases of aggressive lymphoma with spontaneous regression in their article published in 2007 [10]. Eight of the 15 cases had extranodal localization. A tendency implying spontaneous tumor regression was found in the 2 weeks following the

biopsy. Accordingly, if the remaining lymph node shows a significant decrease in size during this space of time, it might be worth to follow the strategy of “watchful waiting”.

Malignant oral lymphomas are rare entities, they represent only 2–5% of oral neoplastic disorders, nevertheless they are the third most frequent oral malignancies [11]. Extranodal B-cell non-Hodgkin lymphomas of the head and neck region might develop from the root of tongue, the soft palate, the tonsils and the nasopharynx, thus they can cause a large variety of symptoms. Until now only rare cases of spontaneous regression among the oral lymphomas have been reported (mainly following local excision or simple sampling with biopsy) [12–14]. In our patient, DLBCL has been shown during the histological tests of the mass causing dysphonia.

DLBCL is the most frequent form of non-Hodgkin lymphomas, but this entity itself is also heterogeneous: nowadays more than 60% of the patients respond well to the treatment, but in nearly half of patients the chances of survival can not be improved. In 2000, an American

Table 1 Mechanisms leading to spontaneous tumor regression according to Papac [4]

Mechanisms leading to spontaneous tumor regression	Example
Immunological mechanisms	Regression of Kaposi's sarcoma in a patient treated with steroids due to psoriasis, after omission of the steroids
Mechanisms relating to endocrine mechanisms	Remission of malignant melanoma in mothers after the delivery
Elimination of the carcinogenic factor	Stopping smoking led to the disappearance of the preinvasive carcinoma of the bronchus
Apoptosis	Spontaneous regression of a stage IV. neuroblastoma
Epigenetical mechanisms	Hypo/hypermethylation of the genome in retinoblastoma
Psychological factors	The role of psycho-neuro-immune mechanisms in the partial regression of tumors

research team attributed the cause of the highly different behavior of the tumor to the molecular heterogeneity of DLBCL [1], and they performed gene expression tests in order to establish it more exactly. According to the gene expression profiles, two molecularly different forms of DLBCL have been found, reflecting different stages of the B-cell differentiation: 1. germinal center B cell-type (GCB) and 2. activated B cell-type (ABC). This classification also suggests clinical and prognostic difference between these two groups [15]. While the average 5-year survival rate of the patients having received standard therapy was 52%, if survival has been analyzed according to molecular subtype, the 5 year survival time of those belonging to the GCB-type was 76% and of those belonging to the ABC form was 16%—that is, the difference was highly significant [16].

The main difference between GCB and ABC is due to alterations of the intracellular signal transduction: in the former the IL-4 signaling pathways are extensively expressed like the IL-4 target genes, too, e.g. Bcl-6 and HGAL the high expression of which is the independent predictor of the longer survival [17]. The ABC type DLBCLs, due to their higher proliferation activity show a more aggressive clinical behavior and at the time of the diagnosis they are already characterized by increased serum LDH level and intermediate or high IPI-scores [18]. But, according to another approach, the less favorable outcome of the ABC-type DLBCL is also enhanced by the fact that it is generally diagnosed in patients older than those with GCB-type DLBCL, i.e. the ABC-type DLBCL carries a worse IPI-score already by itself [19, 20].

Though our patient belonged to the low-risk group according to the age-adjusted IPI-score, the evaluability of this prognostic marker was considered to be limited because of the extranodal affection. Immunohistochemical markers not associated with the IPI promoted the more exact determination of the risk status: belonging to the ABC group predicts a less favorable outcome than that to the GCB-typevariant (5-year survival is 34%) [21]. Taking into consideration the two independent prognostic markers (aaIPI and Bcl-2 + MUM-1 positivity), the risk status of the patient practically corresponded to the high risk IPI-score [2]. However, the clinical experience confuted all this: following an about 7-year-long untreated (!) status, the patient has neither complaints nor B-symptoms and according to the PET-CT, no metabolic activity due to malignancy can be detected neither in the primary localization nor anywhere else.

DLBCL patients should receive active immunochemotherapy—independent from their gene expression pattern. In case of localized disease, the number of the immunochemotherapeutic cycles can be reduced, generally to 3 instead of 8 cycles and then the local irradiation may be

considered [22–24]. In non-compliant patients with localized disease, as reported above, and if accepted by the patient this kind of immunochemotherapy±radiotherapy might be taken into account.

In conclusion, we present here a localized diffuse large B-cell lymphoma case with spontaneous remission occurred in a patient who refused any specific treatment. This case underlines that oncohematologists should undertake the follow-up not only of patients with good compliance but they also have to accept the individual decision of exceptional patients refusing the offered treatment. Controlling and treating non-compliant patients is an even greater challenge than treatment of cooperating ones.

References

1. Alizadeh AA, Eisen MB, Davis RE et al (2000) Distinct types of diffuse large B-cell lymphoma identified by gene expression profiling. *Nature* 403:503–511
2. Chang CC, McClintock S, Ronald P et al (2004) Immunohistochemical expression patterns of germinal center and activation B-cell markers correlate with prognosis in diffuse large B-cell lymphoma. *Am J Surg Pathol* 28:464–470
3. Hans CP, Weisenburger DD, Greiner TC et al (2004) Confirmation of the molecular classification of diffuse large B-cell lymphoma by immunohistochemistry using a tissue microarray. *Blood* 103:275–282
4. Papac RJ (1999) Spontaneous regression of cancer. *Cancer Treatment Reviews* 22:395–423
5. Sengupta N, MacFie TS, MacDonald TT et al (2010) Cancer immunoediting and “spontaneous” tumor regression. *Path Res and Pract* 206:1–8
6. Fujimoto K, Endo T, Nishio M et al (2009) Complete remission of splenic marginal zone lymphoma after an acute flare-up of hepatitis B in a hepatitis B virus carrier. *Int J Hematol* 90:601–604
7. Drobyski WR, Qazi (1989) Spontaneous regression in non-Hodgkin's lymphoma: clinical and pathogenic considerations. *Am J Hem* 31:138–141
8. Gattiker HH, Wiltshaw E, Galton DAG (1980) Spontaneous regression in non-Hodgkin's lymphoma. *Cancer* 45:2627–2632
9. Krikorian JG, Carol S, Cooney DP et al (1980) Spontaneous regression of non-Hodgkin's Lymphoma: a report of nine cases. *Cancer* 46:2093–2099
10. Abe R, Ogawa K, Maruyama Y et al (2007) Spontaneous regression of diffuse large B-cell lymphoma harbouring epstein-barr virus: a case report and review of the literature. *J Clin Exp Hematopathol* 47:23–26
11. Evans LS, Hancock B (2003) Non-Hodgkin lymphoma. *The Lancet* Vol 362:139–146
12. Daly RM, Healy CM, Toner ME et al (2008) Spontaneous regression of non-Hodgkin's lymphoma in the oral cavity after incisional biopsy. *Br J Oral Maxillofac Surg* 46:223–225
13. Savarrio L, Gibosn J, Dunlop DJ et al (1999) Spontaneous regression of an anaplastic large cell lymphoma in the oral cavity: first reported case and review of the literature. *Or Onc* 35:609–613
14. Koga M, Kusakawa J, Havabuchi N (2003) Spontaneous regression of extranodal malignant lymphoma occurred in the gingiva. *Or Onc* 39:323–324

15. Iqbal J, Greiner TC, Patel K et al (2009) Gene expression profiling in lymphoma diagnosis and management. *Best Pract & Res Clin Haem* 22:191–210
16. Camilleri-Broet S, Crinière E, Broet P et al (2006) A uniform activated B-cell-like immunophenotype might explain the poor prognosis of primary central nervous system lymphomas: analysis of 83 cases. *Blood* 107:190–196
17. Lu X, Nechushtan H, Ding F et al (2005) Distinct IL-4-induced gene expression, proliferation, and intracellular signaling in germinal center B-cell like and activated B-cell –like diffuse large-cell lymphomas. *Blood* 105(7):2924–2932
18. Barrans SL, Carter I, Owen RG et al (2002) Germinal center phenotype and bcl-2 expression combined with the International Prognostic Index improves patient risk stratification in diffuse large B-cell lymphoma. *Blood* 99:1136–1143
19. Armitage JO (2008) Is lymphoma occurring in the elderly the same disease? *Leuk Lymphoma* 49:14–6
20. Gutiérrez A, Mestre F, Pérez-Manga G, Rodríguez J (2010) Diffuse large B-cell lymphoma in the older. *Crit Rev Oncol Hematol* Mar 18. [Epub ahead of print] doi:[10.1016/j.critrevonc.2010.02.009](https://doi.org/10.1016/j.critrevonc.2010.02.009)
21. Liu Y-H, Xu FP, Zhuang HG et al (2008) Clinicopathologic significance of immunphenotypic profiles related to germinal center and activation B-cell differentiation in diffuse large B-cell lymphoma from Chinese patients. *Hum Path* 39:875–884
22. Pfreundschuh M (2010) How I treat elderly patients with diffuse large B-cell lymphoma. *Blood* 116:5103–10
23. Miller TP, Unger JM, Spier CM et al (2004) Effect of adding rituximab to three cycles of CHOP plus involved –field radiotherapy for limited –stage aggressive diffuse B-cell lymphoma (SWOG-0014). *Blood* 104:48a
24. Persky DO, Unger JM, Spier CM et al (2008) Phase II study of rituximab plus three cycles of CHOP and involved –field radiotherapy for patients with limited-stage aggressive B-cell lymphoma: Southwest Oncology Group study 0014. *J Clin Oncol* 26(14):2258–2263