

**CASE REPORT****Epidermoid Carcinoma Arising in Warthin's Tumor**

Filiz BOLAT,<sup>1</sup> Fazilet KAYASELCUK,<sup>1</sup> Alper Nabi ERKAN,<sup>2</sup> Can Alper CAGICI,<sup>2</sup> Nebil BAL,<sup>1</sup> Ilhan TUNCER<sup>1</sup>

Departments of <sup>1</sup>Pathology and <sup>2</sup>Ear-Throat-Nose, Başkent University Faculty of Medicine, Adana Teaching and Medical Research Center, Adana, Turkey

**Warthin's tumor is a well-defined salivary gland neoplasm consisting of benign epithelial and lymphoid components. However, malignant transformation is extremely rare and the differential diagnosis of metastasis from an epidermoid carcinoma**

**in Warthin's tumor is important. We present a case with epidermoid carcinoma arising in Warthin's tumor of parotid gland in a 48-year-old woman, and differential diagnosis is discussed.** (Pathology Oncology Research Vol 10, No 4, 240–242)

**Keywords:** Epidermoid carcinoma, Warthin's tumor

**Introduction**

Warthin described papillary cystadenoma lymphomatosum (or adenolymphoma) in 1929.<sup>1-3</sup> It is a benign salivary gland neoplasm occurring principally in the parotid glands of men in the sixth and seventh decades of life.<sup>1-5</sup> In 10% of cases, there are bilateral or multiple tumors.<sup>1,3,4</sup> Warthin's tumor accounts for about 15% of all benign and malignant epithelial neoplasms of the parotid gland. They consist of both epithelial and lymphoid elements. Warthin's tumor is usually asymptomatic or present as slowly-growing painless masses.<sup>1</sup> Malignant transformation of the lymphoid component is relatively common.<sup>3</sup> However, epithelial malignancy in Warthin's tumor is extremely rare, and exists in three forms, as epidermoid carcinoma, adenocarcinoma, and undifferentiated carcinoma.<sup>2</sup> Here we describe a patient who developed epidermoid carcinoma (squamous cell carcinoma) within a Warthin's tumor of the parotid gland.

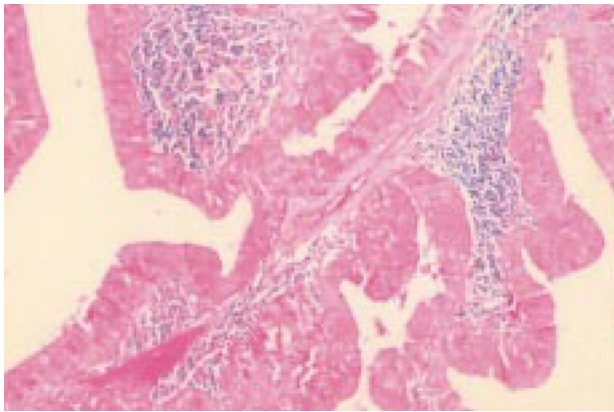
**Case Report**

A 48-year-old woman presented with a painless, slowly growing mass in her left parotid gland region. It had been present for the last five months, but had significantly enlarged within the previous two weeks. Physical exami-

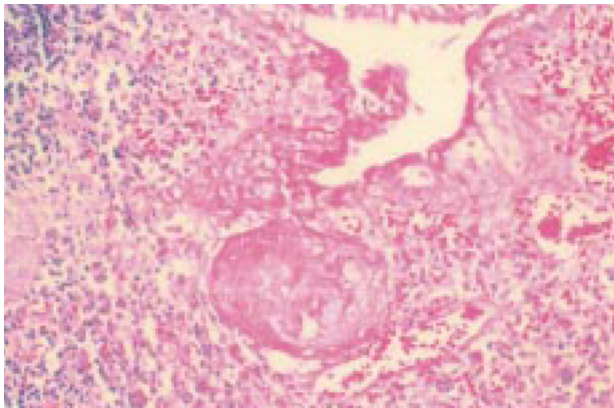
nation revealed a movable mass in the left parotid gland, but no other abnormalities. Computerized tomography (CT) scanning examination disclosed a 3x3 cm solitary tumor mass in the left parotid gland. The patient was referred for fine-needle aspiration biopsy (FNAB). In FNAB sampling, sheets of flat polyhedral oncocytes among amorphous debris and lymphocytes were seen, and thus it was diagnosed as Warthin's tumor. There were no malignant epithelial cells. The patient underwent a superficial lobectomy of the parotid gland. The removed mass was well encapsulated, measuring 5x4x2 cm in size. The cut section was mostly solid, partially cystic and yellow in color. Histologically, the major parts of the tumor were composed of papillary cystic structures lined by double-layered and, in some places, pseudo-stratified oncocytic epithelial cells surrounded by lymphoid stroma (*Figure 1*). Benign squamous metaplastic areas in lymphoid nodules were also found occasionally (*Figure 2*). The minor peripheral parts of the tumor were composed of atypical squamous cells arranged in tightly packed solid nests (*Figure 3*). The tumor cells had slightly eosinophilic cytoplasm, the nuclei were large and vesicular with prominent nuclei. Ischemia and necrosis were seen. Immunohistochemically, epithelial membrane antigen (EMA) and cytokeratins were equally positive both in benign oncocytic and malignant squamous cells (*Figure 4*). Strong linear expression of collagen type IV was seen at the epithelial-stromal interface in benign Warthin's tumor structures, but no immunoreactivity could be detected around carcinoma foci. Based on these gross histological and immunohistochemical findings, the lesion was finally

Received: Sept 19, 2004; accepted: Oct 30, 2004

Correspondence: Dr. Filiz BOLAT, Başkent Üniversitesi, Patoloji A.D., Adana Hastanesi, Yüreğir 01250, Adana, Turkey. Tel: +90 322 327 2727, fax: +90 322 3271276, e-mail: drfilizbolat@yahoo.com.



**Figure 1.** Warthin tumor with papillary proliferation and small lymphoid areas (HE, x200)



**Figure 2.** Squamous metaplastic areas in salivary gland (HE, x200)

diagnosed as epidermoid carcinoma arising in Warthin's tumor. Lymph nodes obtained by the functional neck dissection were negative for neoplasm.

Follow-up of the patient for six months revealed no evidence of recurrence and metastatic neoplasm. After surgical therapy, the patient was irradiated with 3 cGy to the neck and parotid region.

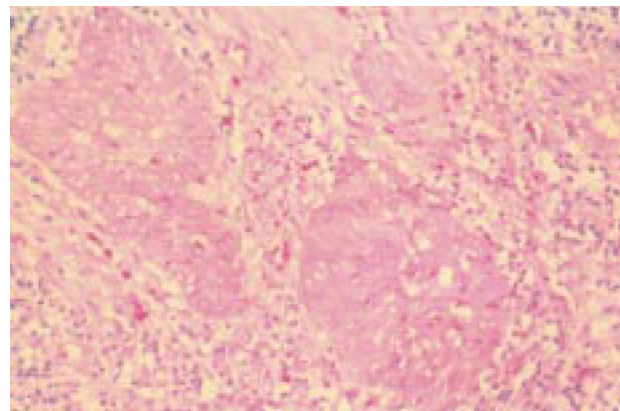
### Discussion

Malignant tumors evolving from pre-existing Warthin's tumors are extremely rare and their incidence has been estimated to be 0.3% of all Warthin's tumor cases.<sup>1-5</sup> Damjanov et al reported only nine cases with epithelial malignancy arising within a Warthin's tumor: four adenocarcinomas, three squamous cell carcinomas, and two undifferentiated tumors.<sup>5</sup> Up to 1999, approximately 30 cases with epidermoid carcinoma arising in Warthin's tumor have been reported in the literature.<sup>1-5</sup>

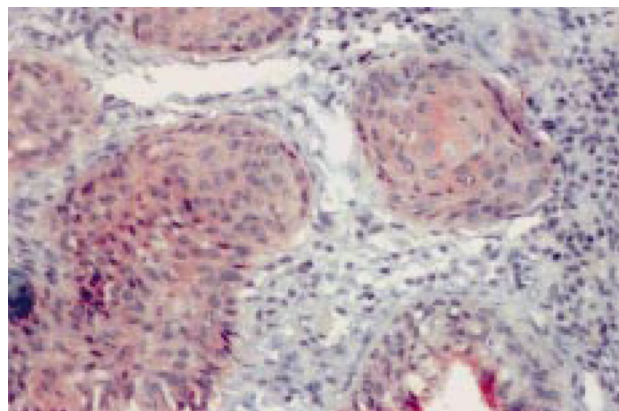
The pathogenesis of the development of malignant tumors in pre-existing Warthin's tumor is uncertain, but

Damjanov et al<sup>5</sup> and Gunduz et al<sup>2</sup> postulated that epidermoid carcinoma arises from squamous metaplastic areas. With the aid of electron microscopy, Damjanov et al demonstrated the presence of keratin cytoskeleton in cylindrical, oncocytic cells of Warthin's tumor. They stated that the transformation of cylindrical cells into squamous cells suggests a carcinoma arising from the foci of squamous metaplasia.<sup>5</sup> An infection, mechanical trauma or large tumor that causes ischemia and necrosis may induce the transformation from cylindrical cells to squamous cells.<sup>2,5</sup> Squamous metaplasia cannot be seen in every Warthin's tumor where ischemia and necrosis occur. In the literature, tumors with squamous metaplasia and necrosis could be named as metaplastic Warthin's tumor. Moreover, metaplastic epithelium in metaplastic Warthin's tumor does not have atypical cytological features and infiltrating growth pattern.<sup>3</sup> In our case, we detected areas of ischemia and necrosis. These areas may be a proof for etiology of squamous metaplasia and squamous carcinoma.

Metastasis to the lymphoid component of the Warthin's tumor should also be considered for differential diagnosis.



**Figure 3.** Strands of invasive squamous cell carcinoma (HE, x200)



**Figure 4.** Squamous cell carcinoma areas displayed positive staining for cytokeratin (x200)

Because of the lymphatic drainage from the scalp, face, external ear, eyelids, and nose to the parotid lymph nodes, it is not surprising that an epidermoid carcinoma and melanoma arising in these areas are the sources of the metastatic malignant tumors most often found in the parotid gland.<sup>2</sup> In our case, a negative systemic screening for primary cancer, and no metastasis in regional lymph nodes confirmed the diagnosis of the carcinoma originating from a Warthin's tumor. To distinguish metastasis from a primary carcinoma of another site, the presence of transitional zones from benign oncocytic component to frank malignant epithelium is also very important. Such a transition zone was difficult to find in the present case because of necrosis.

Treatment of this tumor is primarily surgical, consisting of adequate excision of the primary site with or without radical neck dissection. When the patient with epidermoid carcinoma is free of distant metastasis, only surgical therapy is sufficient. However, neither radiotherapy nor chemotherapy changed the prognosis, and these patients died earlier.<sup>2</sup> The long-term prognosis of these patients is not clear; one-year disease-free survival has been reported in the literature.<sup>4</sup> Most of the reported cases with malignant transformation in Warthin's tumor did not show dis-

tant metastasis. However, local lymph node metastasis was reported to be common.<sup>2,4</sup> We did not discover either distant or lymph node metastasis in our patient, and she was disease-free at 6-month follow-up.

Malignant change in a Warthin's tumor may be suggested clinically by a rapid enlargement of a long-standing mass.<sup>2</sup> Biopsy and histopathological examination are necessary to observe malignant change in Warthin's tumor.

### References

1. *Huvos AG, Paulino AFG*: Salivary Glands. In: Diagnostic Surgical Pathology. (Eds: Stenberg SS), 3<sup>rd</sup> edition, Lippincott Williams&Wilkins, Philadelphia, 1999, pp 861-862
2. *Gunduz M, Yamanaka N, Hotomi M, et al*: Squamous cell carcinoma arising in a Warthin's tumor. *Auris Nasus Larynx* 26:355-360, 1999
3. *Skalova A, Michal M, Nathansky Z*: Epidermoid carcinoma arising in Warthin's tumour: a case study. *J Oral Pathol Med* 23:330-333, 1994
4. *Morrison GAJ, Shaw HJ*: Squamous carcinoma arising within a Warthin's tumor of the parotid gland. *J Laryngol Otol* 102:1189-1191, 1988
5. *Damjanov I, Sneff EM, Delorme AN*: Squamous cell carcinoma arising in Warthin's tumor of the parotid gland. A light, electron microscopic, and immunohistochemical study. *Oral Surg Oral Med Oral Pathol* 55:286-290, 1983