

**CASE REPORT****Talc Inhalation is a Life-Threatening Condition**

Yoram DEKEL, Lea RATH-WOLFSON, Carlos RUDNIKI, Rumelia KOREN

Department of Pathology, Hasharon Hospital, Rabin Medical Center, Campus Golda, Petah Tikva,  
and Sackler Faculty of Medicine, Tel Aviv University, Tel Aviv, Israel

**A case of rapidly progressive disease and pulmonary hypertension due to chronic cosmetic talc inhalation is presented. Although an uncommon cause of pulmonary hypertension, talc, especially through intravenous administration, should be included in the etiology of parenchymal pul-**

**monary hypertension. In our case talc inhalation was inadvertent, causing fulminant disease leading to the patient's death. To our knowledge, this is the first case of inadvertent talc inhalation causing death in adult patient. (Pathology Oncology Research Vol 10, No 4, 231–233)**

*Keywords:* talc inhalation, fibrosis, adult respiratory distress syndrome

**Case Report**

A 42-year old woman presented with one month history of dry cough, dyspnea on exertion, as well as lip, heel and pedal edema. On background she had mild arterial hypertension well controlled with Atenolol. There was no history of smoking, occupational exposure to talc or other irritants or use of illicit drugs.

On physical examination she appeared well, with respiratory rate of 18/minute. The lungs were clear. Cardiac examination revealed a systolic murmur 2/6 on the left parasternal border, becoming louder with inspiration, split second heart sound with loud p2. The liver and the spleen were not palpable.

The electrocardiogram was compatible with right ventricular hypertrophy. The echocardiogram revealed marked dilatation of the right atrium and the right ventricle with paradoxical movement of the interventricular septum. On Doppler examination, severe tricuspid insufficiency was noticed. Neither atrial septal defect nor ventricular septal defect was seen. The pulmonary artery pressure was calculated to be 85 mmHg. Chest X-ray showed only increased interstitial markings in the base of the right lung. Arterial blood gases on room air were: pH – 7.47,

pO<sub>2</sub> – 8.9 kPa, pCO<sub>2</sub> – 2.06 kPa, HCO<sub>3</sub><sup>–</sup> – 17 mmol/L. Pulmonary function tests were compatible with small airway disease. A perfusion lung scan was normal. During the third day of hospitalization, the patient suddenly developed clinical and radiological findings of pulmonary edema, and despite intensive treatment the patient died.

*Post mortem examination*

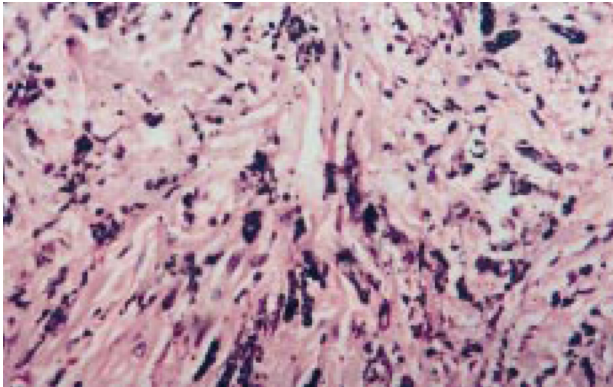
The right lung weighed 1100 grams and the left lung 1000 grams. There were bilateral pleural effusions and severe lung edema. The pleural surface was smooth with focal black pigmentation. On cut surface, the lung tissue was elastic, red in color with small dark-brown elastic nodules measuring 3–5 mm in diameter. There was no thrombosis seen in the lungs. The trachea and the bronchi were edematous. The heart weighed 250 grams. The pericardium was normal. The tricuspid valve dilated measuring 5 cm in diameter. There was hypertrophy of the right ventricle to 1.1 cm and of the left ventricle up to 1.4 cm thickness. The pulmonary artery was dilated. Other structures of the heart looked normal. There were no ischemic changes or thrombosis, and the coronary arteries were open without atherosclerotic changes. The rest of the organs did not show any special changes.

Microscopic examination of the lungs demonstrated diffuse interstitial fibrosis and pneumonitis with localized, nodular accumulations of granular, irregular, black amorphous material (*Figure 1*). In polarizing microscope needle-shaped birefringent crystals were seen (*Figure 2*). These crystals were located either singly or in clusters and

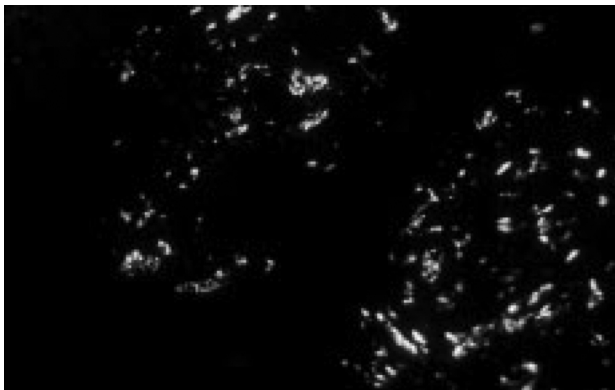
*Received:* Oct 5, 2004; *accepted:* Nov 12, 2004

*Correspondence:* Rumelia KOREN MD, Department of Pathology, Sackler School of Medicine, Tel Aviv University, Ramat Aviv, Tel Aviv 69978, Israel; Fax: 972-3-9372349, e-mail: rumelia@isdnmail.co.il

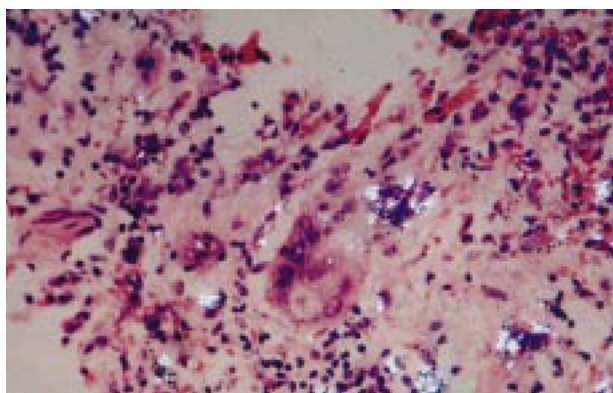
measured up to 5  $\mu\text{m}$  in length. Foreign body giant cells and collagen fibers were accompanied by the birefringent crystals (Figure 3). They were located at the interstitium and around small blood vessels. The small blood vessels presented thickening of the walls and did not show any mural inflammation or intimal proliferation.



**Figure 1.** Microscopic examination of the lungs demonstrated diffuse interstitial fibrosis and nodular accumulations of granular, irregular, black amorphous material.  $\times 100$ , HE



**Figure 2.** The same microscopic field examined in polarizing microscope showed needle-shaped birefringent crystals.  $\times 100$ , HE



**Figure 3.** Birefringent crystals accompanied by foreign body giant cells and collagen fibers. Polarized light,  $\times 400$ , HE

Using back-scattering electron diffraction techniques, we found the crystal particles to exclusively contain magnesium and silicate, have a plate-like configuration, and be most compatible with crude talc. However, the talc particles were exceedingly large and not of the usual granular configuration. The particles were consistent with talc, but a small amount of aluminum was present, which may indicate the inhalation of some other chemical compound (Figures 4, 5).

### Discussion

Talc is a mineral compound with unique attributes and significant commercial importance. As used in consumer products, talc has a long and proven history of safe use. Direct consumer applications include body powders, other cosmetic formulations, pharmaceutical tableting, and some confectionery food products. Consumer exposure to talc-containing products is at least 350 times lower than permissible industrial exposure.<sup>26</sup> Exposure to talc dust probably contributed to the elevated rate of non-malignant respiratory disease, particularly pulmonary fibrosis.<sup>12</sup>

A review of the literature reveal lung overload changes in animals exposed to cosmetic talc aerosol concentrations.<sup>25</sup> A model simulating chronic talc inhalation exposure of rats and mice predicted lung burdens of 2-3 mg talc/g lung (wet wt) if animals were exposed to 17 mg talc/ $\text{m}^3$  for 2 years, and deposition and clearance of talc were unchanged by continued exposure. Histological alterations in lung tissue consisted of only a modest, diffuse increase of talc-containing, free macrophages within alveolar spaces in both rat and mouse groups exposed to the highest level of talc for 20 days.<sup>21</sup>

Rapidly progressive pulmonary hypertension developed in our patient together with the granulomatous reaction to talc crystals. Pulmonary granulomatosis has been described in drug addicts who used talc to dilute the illicit drug before intravenous injection.<sup>13</sup>

In some patients, widespread granulomatosis develops in the lung interstitium with sparing of the lung vasculature,<sup>2</sup> while in others diffuse vascular reaction can be seen.<sup>13,14</sup> In both instances, however, pulmonary hypertension develops.

Recently, several reports of pulmonary hypertension secondary to talc microemboli have been described. Most of the patients were heroin addicts<sup>16</sup> who also had a history of intravenous injection of medicaments originally intended for oral use, e.g. methylphenidate, pentazocine.<sup>15</sup> Several reports of morbidity, usually pneumonitis or fibrosis, caused by talc inhalation has been published.<sup>1,3-6,8,10,11,19,22,23</sup> The talc inhalation was either occupational or of cosmetic use.

The pathological features of talc inhalation have been described either as fibrosis reaction that can be diffuse interstitial or irregular nodular, or as non-caseating granulomatous reaction. In the latter, microscopic examination under polarized light reveals birefringent needle-shaped particles in multinucleated giant cells and macrophages.



**Figure 4.** Inorganic particles appear as bright, white areas and spots in the black background of the backscattered frame. Backscattered electron microscopy of ribbons cut from paraffin block in the electron microscope (JEOL 100CX)



**Figure 5.** Elemental analysis of the inorganic particles

The particles size on the average 5  $\mu\text{m}$  in most of the cases.<sup>20</sup> These pathological features differ from the pulmonary findings seen after intravenous talc injection. In the latter the particles are larger and characteristic intravascular and perivascular granulomas can be seen.<sup>7,18</sup>

In our case, the size of the particles, the location of the granulomas and the lack of intravascular and perivascular lesions support the inhalation as the mode of entry of the talc into the lungs.

Careful examination with the patient's family members and friends revealed an excessive cosmetic use of talc for herself and her little children, exposing her to chronic talc inhalation, a mode of exposure that has been described previously.

Generally talc inhalation results in lung disease.<sup>9</sup> Only three cases of rapidly progressive disease resulting in mortality due to talc inhalation have been described previously, two cases of infants died of talc inhalation,<sup>17</sup> and one of a patient who committed suicide by purposed inhalation of large amount of talc.<sup>24</sup>

In our case the talc inhalation was inadvertent, causing fulminant disease leading to the patient's death in three days. To our knowledge, this is the first case of inadvertent talc inhalation causing death in adult patient.

## References

1. Abraham JL, Brambilla C: Particle size for differentiation between inhalation and injection pulmonary talcosis. *Environ Res* 21: 94-96, 1980
2. Arnett EN, Battle WE, Russo JV, et al: Intravenous injection of talc-containing drugs intended for oral use. A cause of pulmonary granulomatosis and pulmonary hypertension. *Am J Med* 60: 711-718, 1976
3. Avolio G, Galiotti F, Oliaro A, et al: Talcosis as an occupational disease. Case histories. *Minerva Med* 80: 269-273, 1989
4. Bignon J, Brochard P: Pulmonary fibrosis and inorganic particles. *Rev Fr Mal Respir* 11: 371-382, 1983
5. Canessa PA, Torracca A, Lavecchia MA, et al: Primary acute pulmonary cavitation in asymptomatic sarcoidosis. *Sarcoidosis* 6: 158-160, 1989
6. Cotton WH, Davidson PJ: Aspiration of baby powder. *N Engl J Med* 313: 1662, 1985
7. Crouch E, Churg A: Progressive massive fibrosis of the lung secondary to intravenous injection of talc. A pathologic and mineralogic analysis. *Am J Clin Pathol* 80: 520-526, 1983
8. Egan AJ, Tazelaar HD, Myers JL, et al: Munchausen syndrome presenting as pulmonary talcosis. *Arch Pathol Lab Med* 123: 736-738, 1999
9. Gibbs AE, Pooley FD, Griffiths DM, et al: Talc pneumoconiosis: a pathologic and mineralogic study. *Hum Pathol* 23:1344-1354, 1992
10. Gutermuth M, Schirg E, Steinbacher D, et al: Accidental aspiration of baby powder. Radiographic findings, preventive and therapeutic aspects. *Intensivmed Prax* 2: 83-92, 1980
11. Hollinger MA: Pulmonary toxicity of inhaled and intravenous talc. *Toxicol Lett* 52: 121-127, 1990
12. Honda Y, Beall C, Delzell E, et al: Mortality among workers at a talc mining and milling facility. *Ann Occup Hyg* 46: 575-585, 2002
13. Hopkins GB: Pulmonary angiothrombotic granulomatosis in drug offenders. *JAMA* 221: 909-911, 1972
14. Lamb D, Roberts G: Starch and talc emboli in drug addicts' lungs. *J Clin Pathol* 25: 876-881, 1972
15. Lundquest DE, Young WK, Edland JF: Maternal death associated with intravenous methylphenidate (Ritalin) and pentazocine (Talwin) abuse. *J Forensic Sci* 32: 798-801, 1987
16. Magnan A, Ottomani A, Garbe L, et al: Respiratory failure in a HIV seropositive heroin addict female. *Ann Fr Anesth Reanim* 10: 74-76, 1991
17. Motomatsu K, Adachi H, Uno T: Two infant deaths after inhaling baby powder. *Chest* 75: 448-450, 1979
18. Oubeid M, Bickel JT, Ingram EA, et al: Pulmonary talc granulomatosis in a cocaine sniffer. *Chest* 98: 237-239, 1990
19. Pairaudeau PW, Wilson RG, Hall MA, et al: Inhalation of baby powder: an unappreciated hazard. *BMJ* 302: 1200-1201, 1991
20. Pfenninger J, D'Apuzzo V: Powder aspiration in children. Report of two cases. *Arch Dis Child* 52: 157-159, 1977
21. Pickrell JA, Snipes MB, Benson JM, et al: Talc deposition and effects after 20 days of repeated inhalation exposure of rats and mice to talc. *Environ Res* 49: 233-245, 1989
22. Reyes de la Rocha S, Brown MA: Normal pulmonary function after baby powder inhalation causing adult respiratory distress syndrome. *Pediatr Emerg Care* 5: 43-48, 1989
23. Scancarello G, Romeo R, Sartorelli E: Respiratory disease as a result of talc inhalation. *J Occup Environ Med* 38: 610-614, 1996
24. Steele AA: Suicidal death by aspiration of talcum powder. *Am J Forensic Med Pathol* 11: 316-318, 1990
25. Wehner AP: Biological effects of cosmetic talc. *Food Chem Toxicol* 32: 1173-1184, 1994
26. Zazenski R, Ashton WH, Briggs D, et al: Talc: occurrence, characterization, and consumer applications. *Regul Toxicol Pharmacol* 21: 218-229, 1995