

CASE REPORT

Cystic Thymoma

Ralf J RIEKER,¹ Sebastian AULMANN,¹ Philipp A SCHNABEL,¹ Falk-Udo SACK,² Herwart F OTTO,¹ Gunhild MECHTERSHEIMER,¹ Peter SCHIRMACHER,¹ Hendrik BLÄKER¹

¹Department of General Pathology, ²Department of Cardiac Surgery, University Hospital, Heidelberg, Germany

Thymic cysts are rare lesions located along the anatomical course of the third pharyngeal pouch. While most of the cases represent congenital cysts, they may also be related to neoplasms. We report a case of a micronodular thymoma with lymphoid

stroma, which was completely built of small cysts, discuss the pathologic features of this tumor type and review the etiology and other aspects of thymic cysts. (Pathology Oncology Research Vol 11, No 1, 57–60)

Key words: thymic cysts, cystic thymoma, micronodular thymoma

Introduction

Thymic cysts were first described by Lieutaud in 1832 (cited in Dubois, 1850)² who found suppurative changes of the thymus in two post-mortem cases. Both patients had been young men who had suffered from syphilis and caseous pulmonary tuberculosis. Dubois in 1850 reported cystic changes of the thymus in three newborns that died of congenital syphilis and, discussing the previous two cases of Lieutaud, attributed the cystic changes to syphilis but not tuberculosis.² In 1912, Ribbert raised doubts concerning the causative role of syphilis in thymic cysts as he described thymic cysts that were formed of enlarged Hassall's corpuscles filled with keratin and necrotic debris.¹⁴

Thymic cysts are believed to represent different entities, congenital, inflammatory and neoplastic cysts.⁷ Congenital cysts can be found along the anatomical course of the third pharyngeal pouch, and therefore may even be located at the lateral neck. Suster and Rosai¹⁹ hypothesized that inflammatory cysts may be due to an acquired inflammatory process. Neoplastic cysts are encountered in up to 40% of thymomas,¹⁵ more frequently in larger tumors than in smaller ones.

The surgical treatment of thymic cysts dates back to 1901, when Polloson and Piery operated on an 18-month-old boy with congenital polycystic cervical thymic tumor, who died on the day of operation.¹³ The first complete and

successful operation on a cervical thymic cyst was performed by Hyde in 1944,⁴ and that of mediastinal thymic cyst by Bradford and by Smart in 1947.^{1,16} In the case herein presented, we report a cystic micronodular thymoma with lymphoid stroma and follicular hyperplasia, and discuss several aspects of thymic cysts.

Case report

An 80-year-old female patient with no history of autoimmune disease was admitted to the Department of Cardiac Surgery. The diagnosis revealed severe coronary vessel disease. The patient suffered from unstable angina pectoris, and urgent coronary artery bypass graft (CABG) operation was indicated. In her medical history she had arterial hypertension and diabetes mellitus type II. Due to coronary disease involving 3 vessels, and two myocardial infarctions, the left ventricular function was severely reduced. During CABG surgery a 7x4x4 cm well-circumscribed tumor of the anterior mediastinum was found, resected and sent for frozen sectioning. The intraoperative histologic diagnosis was a benign cystic mediastinal tumor. The postoperative course was complicated by the severely reduced left ventricular function. Despite of high intravenous doses of catecholamines and supportive therapy by an intraaortic balloon pump, the patient died on the second postoperative day due to cardiac failure.

Pathology

We received a 7x4x4 cm specimen with sparse adjunct fatty tissue. The tumor was completely built of multiple cysts of sizes up to 7 mm (*Figure 1a,b*) which partly con-

Received: Febr 17, 2005; accepted: March 10, 2005

Correspondence: RJ RIEKER, Department of General Pathology, University Hospital, INF 220/221, 69120 Heidelberg, Germany; Tel: +49 6221 56 2666, fax: +49 6221 56 5251. e-mail: ralf.rieker@med.uni-heidelberg.de

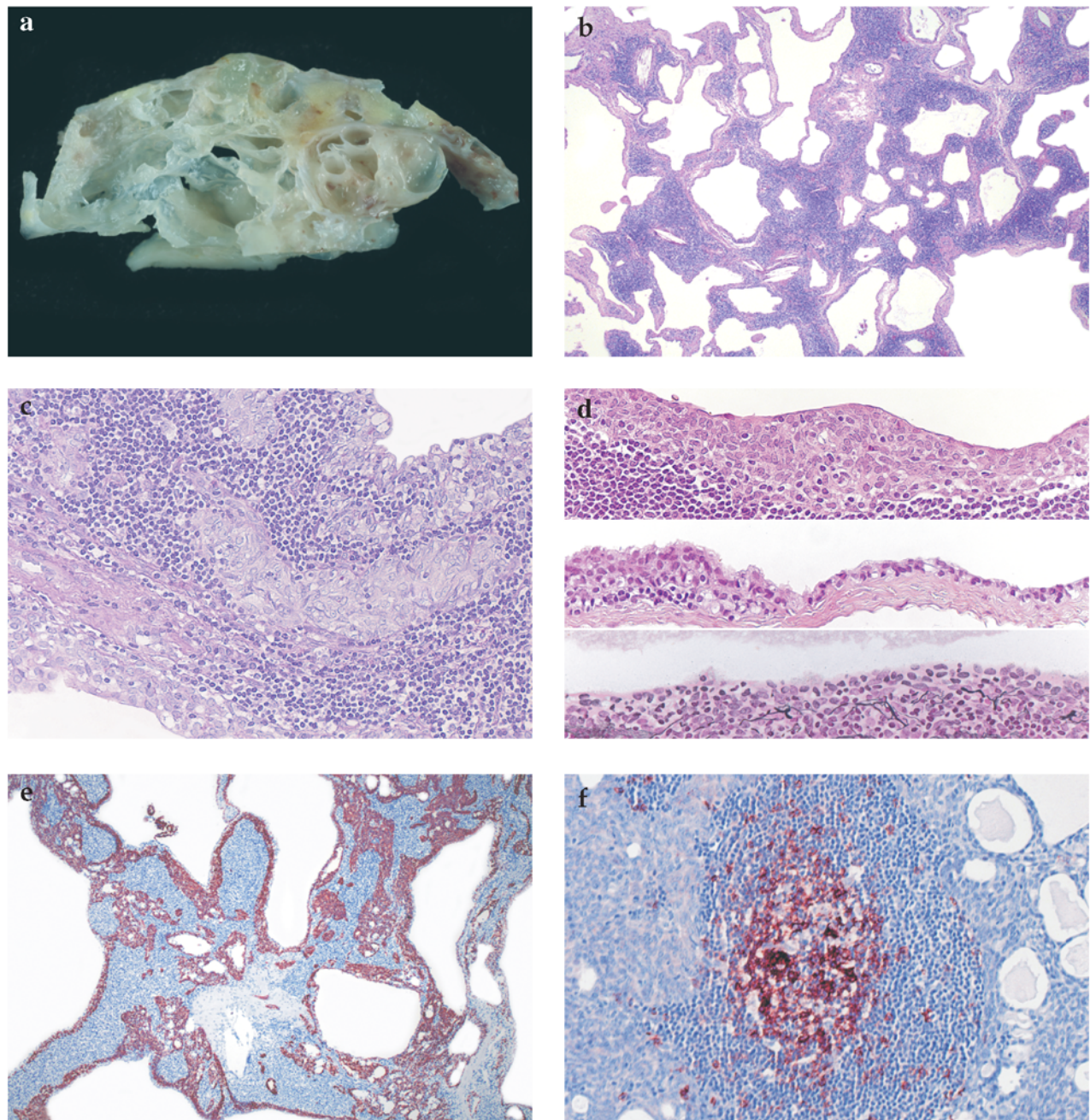


Figure 1. (a) Photograph of the specimen with multiple cysts, (b) Microscopic features in the overview with cholesterol crystals (PAS, x2,5), (c) At high magnification, some epithelial cells exhibit a spindle cell appearance. The nuclei are round and oval (PAS, x20), (d) Several aspects of the epithelium delineating the cysts (hematoxylin and eosin, and Tibor PAP x20), (e) Microscopic features in the overview with the antibody 34βE12 (DAKO, x2,5) for the epithelial component, (f) CD20 staining of a lymphoid follicle (DAKO, x10).

tained clear fluid. Histologically, there was a clear separation of an unsuspecting lymphocytic component and cells with a spindle/oval shape, which had a weakly eosinophilic cytoplasm and round to oval nuclei with inconspicuous nucleoli (Figure 1c). The cells were positive for the high-molecular-weight cytokeratin marker 34βE12 (DAKO, Hamburg, Germany; Figure 1e). The

cysts were delineated by a flat, sometimes cuboidal to squamous-like epithelium beneath which a small band of collagen could be seen (Figure 1d). In circumscribed areas regressive changes with cholesterol crystals could be detected (Figure 1b). Furthermore, follicular hyperplasia was present (Figure 1f, CD20, DAKO). The epithelial cells were not positive for CD20, most of the lymphocytes

were T cells positive for CD5 (not shown). Adjacent to the tumor there was sparse fatty tissue with lipomatous-atrophic thymus and focal follicular hyperplasia (not shown). The final diagnosis was cystic micronodular thymoma with lymphoid stroma.

Discussion

Thymic cysts are believed to represent different entities, congenital, inflammatory and neoplastic cysts.⁷ Most of the thymic cysts can be explained as sequestered remnants of the thymopharyngeal duct system. The thymus is derived from the ventral part of the third pharyngeal pair of pharyngeal pouches, whereas the parathyroid gland is derived from the dorsal part. During the embryological descent from the lateral neck to the manubrium sterni, remnants of the pharyngeal system may persist and lead to the formation of congenital thymic cysts. This theory is further supported by the relatively frequent observation of endocrine (mostly parathyroid) gland inclusions within the cysts.³

Congenital thymic cysts have an approximately equal sex distribution, and mediastinal cysts are more frequent than cervical thymic cysts (2.5:1).⁵ Cervical cysts have been extensively reviewed by Guba³ who examined 56 histologically confirmed cases. Seventy percent of the cases were right-sided and in 90% the initial symptom was a painless swelling. The incidence was highest in the pediatric group. In the mediastinum, thymic cysts are rare. Wychulis reviewed 1064 mediastinal cysts: 196 were benign, of which only 19 were of thymic origin and only 2 patients were under the age of 30 years.²³ Suster and Rosai reported 18 cases of multilocular thymic cysts in the anterior mediastinum,¹⁹ four of them related to an epithelial tumor of the thymus. They hypothesized that the origin of mediastinal thymic cysts is pathogenetically analogous to cystic conditions in the head and neck region, "for which the common denominator seems to be the induction of cystic transformation in ductal epithelial formations of branchial pouch or related derivation by an acquired inflammatory process". The same authors²⁰ reported one year later 10 cystic thymomas, and emphasized that diagnosis may be difficult due to cystic changes and the inflammatory nature of these tumors. Degeneration of thymic cysts may reduce the identifiable tumor tissue, therefore extensive microscopic sampling is important. Another study of 25 thymomas¹⁰ with prominent cystic and hemorrhagic changes and areas of infarction and necrosis illustrates this well. Inflammatory cysts of the thymus are also reported in conjunction with radiation therapy of the mediastinum, as reported in patients with Hodgkin's disease.¹¹ In 1999, Suster and Moran published 18 cases of sometimes cystic thymomas that showed a micronodular growth pattern associated with lymphoid hyperplasia, and named them micronodular thymoma with B-cell hyperpla-

sia.¹⁸ They interpreted these cases as an unusual morphologic variant of spindle cell thymomas with possible transition to lymphoepithelioma-like carcinomas, as one case had areas of frank poorly differentiated squamous cell carcinoma. Since that time many reports on this special subtype have been published, and in the actual WHO classification these tumors are listed as micronodular thymoma with lymphoid stroma,⁹ for which a medullary cell origin has been postulated.²² Micronodular thymomas should be differentiated from conventional type AB thymomas that sometimes contain single lymphoid follicles. However, lymphocyte-rich areas in micronodular thymoma do not contain epithelium. Another aspect that should be considered is that micronodular thymomas may have a monoclonal B-cell population, so low-grade lymphoma should be excluded.⁹

The herein presented cystic tumor represents an uncommon variant of type A thymoma with a clear division of epithelial and lymphatic components. The lesion was named by Suster and Moran as micronodular thymoma with B-cell hyperplasia,¹⁸ and in the actual WHO classification as micronodular thymoma with lymphoid stroma⁹ with suspected medullary origin.²² The prognosis of this thymoma subtype should be good, as cytogenetic analysis of type A thymomas revealed a stable karyotype with only very few chromosomal imbalances, compared to type B and C thymomas.^{6,12,24} Although there have been reports of thymic carcinomas arising within bland thymic cysts,⁸ and malignant transformation of micronodular thymomas and type A thymomas,^{17,18,21} there have been no reports on recurrence, metastasis or tumor-related death in micronodular thymomas.⁹

References

1. Bradford ML, Mahon HW, Grow JB: Mediastinal cysts and tumors. *Surg Gynecol Obstet* 85: 467-491, 1947
2. Dubois P: Du diagnostic de la syphilis consideree comme une des causes possibles de la mort du fœtus. *Gaz Med de Paris* 21:392-395, 1850
3. Guba AM jr, Adam AE, Jaques DA, et al: Cervical presentation of thymic cysts. *Am J Surg* 136:430-436, 1978
4. Hyde TL, Sellers ED, Owen M: Thymic cyst of the neck: report of a case. *Tex State J Med* 39:539-540, 1944
5. Indeglia RA, Shea MA, Grage TB: Congenital cysts of the thymus gland. *Arch Surg* 94:149-152, 1967
6. Inoue M, Starostik P, Zettl A, et al: Correlating genetic aberrations with World Health Organization-defined histology and stage across the spectrum of thymomas. *Cancer Res* 63:3708-3715, 2003.
7. Krech WG, Storey CF, Umiker WC: Thymic cysts: a review of the literature and report of two cases. *J Thorac Surg* 27: 477-493, 1954
8. Leong AS, Brown JH: Malignant transformation in a thymic cyst. *Am J Surg Pathol* 8:471-475, 1984
9. Marx A, Stroebel P, Marino M, et al: Micronodular thymoma with lymphoid stroma. In: *Pathology and Genetics of Tumours of the Lung, Pleura, Thymus and Heart*. (Eds: WD Travis, E

- Brambilla HK, Müller-Hermelink, CC Harris) World Health Organization of Tumors. IARC Press, Lyon 2004, pp. 167-168
10. *Moran CA, Suster S*: Thymoma with prominent cystic and hemorrhagic changes and areas of necrosis and infarction: a clinicopathologic study of 25 cases. *Am J Surg Pathol* 25:1086-1090, 2001
 11. *Murray JA, Parker AC*: Mediastinal Hodgkin's disease and thymic cysts. *Acta Haematol (Basel)* 71:282-284, 1984
 12. *Penzel R, Hoegel J, Schmitz W, et al*: Clusters of chromosomal imbalances in thymic epithelial tumours are associated with the WHO classification and the staging system according to Masaoka. *Int J Cancer* 105:494-498, 2003
 13. *Pollosson A, Piery M*: Un cas d'epithelioma primitif du Thymus. *Provinc Med* 16:1-4, 1901
 14. *Rippert H*: Die Entwicklungsstörung der Thymusdrüse bei kongenitaler Lues. *Frankfurt Z Pathol* 11:209-218, 1912
 15. *Rosai J, Levine GD*: Tumors of the thymus. In: *Atlas of Tumor Pathology*, 2nd series, fasc 13. Armed Forces Institute of Pathology, Washington DC, 1976, pp 48-49, 207-211,
 16. *Smart J*: A case of large thymic cyst successfully removed from the anterior mediastinum. *Br J Tuberc* 41: 84-88, 1947
 17. *Suster S, Moran CA*: Primary thymic epithelial neoplasms showing combined features of thymoma and thymic carcinoma. A clinicopathologic study of 22 cases. *Am J Surg Pathol* 20:1469-1480, 1996
 18. *Suster S, Moran CA*: Micronodular thymoma with lymphoid B-cell hyperplasia: clinicopathologic and immunohistochemical study of eighteen cases of a distinctive morphologic variant of thymic epithelial neoplasm. *Am J Surg Pathol* 23:955-962, 1999
 19. *Suster S, Rosai J*: Multilocular thymic cyst: an acquired reactive process. Study of 18 cases. *Am J Surg Pathol* 15: 388-398, 1991
 20. *Suster S, Rosai J*: Cystic thymomas. A clinicopathologic study of ten cases. *Cancer* 69:92-97, 1992
 21. *Tateyama H, Saito Y, Fujii Y, et al*: The spectrum of micronodular thymic epithelial tumours with lymphoid B-cell hyperplasia. *Histopathology* 38: 519-527, 2001
 22. *Thomas De Montpreville V, Zemoura L, Dulmet E*: Thymoma with epithelial micronodules and lymphoid hyperplasia: six cases of a rare and equivocal subtype. *Ann Pathol* 22:177-182, 2002
 23. *Wychulis AR, Payne WS, Clagett OT, Woolner LB*: Surgical treatment of mediastinal tumors - a 40 year experience. *J Thorac Cardiovasc Surg* 62: 379-392, 1971
 24. *Zettl A, Strobel P, Wagner K, et al*: Recurrent genetic aberrations in thymoma and carcinoma. *Am J Pathol* 157:257-266, 2000