

DNA Ploidy Pattern in Pure Seminomas

Zoltán SÁPI,¹ Jorgosz SZAPANIDISZ,² Bernadette TÓTH,¹ István BODROGI³

¹Department of Pathology, ²Department of Urology, St. John's Hospital

³Department of Chemotherapy and Clinicopharmacology, National Institute of Oncology

Nuclear extract and image cytometry was used to determine the DNA ploidy pattern of 31 pure seminomas. At least 5-year but usually 10-year follow-up was available to compare the clinical outcome to the DNA ploidy pattern. In 24 cases (77.4%) the DNA indexes (DI) showed tetraploid ($1,8 < DI < 2,2$) pattern confirming the recent cytogenetic and flow cytometric DNA studies of others. However, in 7 cases (22,6%) the tumors were aneuploid. Out of these aneuploid cases 2 had two subpopulations

and 2 had less than 1,8 DI. These latter cases (providing the loss of chromosomal DNA) had elevated AFP levels in serum that raises the question of nonseminomatous transformation without any morphological evidence. Usually, the aneuploid cases had worse prognoses but there was no significant difference. Because of the small number of aneuploid cases wider clinicopathologic studies are required to confirm our results. (Pathology Oncology Research Vol 1, No 1, 71-74, 1995)

Key words: DNA ploidy, image cytometry, seminoma

Introduction

The distinction of seminomas, nonseminomatous germ cell tumors and mixed forms has great clinical importance due to the different treatment of each type. The diagnosis of pure seminomas does not cause any problem. However, if a testicular tumor is too big almost impossible to process the whole tumor in order to decide whether it contains nonseminomatous elements or not. The determination of the blood level of alpha-fetoprotein (AFP) and human chorionadotropin (HCG) is a great help because the elevated values always suggest the presence of nonseminomatous component. Recent studies confirmed the hypothesis that nonseminomatous tumors arise from seminomas (characterized by tetraploid DNA content) by further loss of chromosomal DNA.^{1,2,4,6,11} We selected 31 pure seminomas (by histology) to analyse whether they are all tetraploid tumors and if not, aneuploidy is connected to elevated AFP or to a worse prognosis.

Materials and Methods

Thirty one pure seminomas were selected from the files of the Department of Pathology, St. John's Hospital, Budapest. Detailed histology (we processed the whole

tumor if it was less than 3 cm in diameter) showed no nonseminomatous elements, and all the seminomas were classical. We selected proper tumor areas (one sample/case) containing no necrosis but having enough tumor cells and lymphocytes (*Fig. 1 a and b*). Nuclear extraction was performed by method of Hedley et al.⁸ Following Feulgen staining (hydrolysis 1 N HCL, 60°C, 9 min) measurements were performed with an image analyser, using DNA ploidy software developed by us, fulfilling the criteria of DNA image cytometry described by Carey.⁵ (Microscope linked directly to computerized image analysis system; polychromatic green filter; "grey level" measurement which is assigned a numerical value by a digital converter and relayed to a computer for presentation and analysis; unwanted areas are specifically excluded from measurements; DNA content of a nucleus is quantified as an integrated optical density (IOD) for all pixels analysed within that object and given a single numeric value; results are expressed graphically and DNA ploidy values are calculated with respect to a standard reference population (usually lymphocytes). In each case 20-50 lymphocytes and 100-150 tumor cells were measured.

At least 5-year but usually 10-year follow up was available to compare the clinical outcome to the DNA ploidy pattern. We also examined the TNM status, the hormone levels and the prognosis of the tumors.

Received: May 2, 1995, accepted: June 12, 1995

Correspondence: Zoltán SÁPI, M.D., Szent János Hospital, Department of Pathology, H-1122 Budapest, Diósárok u. 1.




Figure 1 (a) Typical histological picture of pure seminoma (b) Feulgen stained smear of nuclear extraction of the previous case. Note the easily distinguishable tumor cells and lymphocytes.

Results

Twenty-four neoplasms (77.4%) manifested a tetraploid DNA contents ($1.8 < DI < 2.2$), with average of 1.97. *Fig.4*. Seven cases (22.6%) were aneuploid, three of them had higher than tetraploid value (average DI was 2.73). Four cases had lower than tetraploid DI, average DI was 1.64. Interestingly two of these latter cases had two subpopulations each having a characteristic tetraploid one and a lower aneuploid one: 1.79 and 1.76, respectively. These results are shown in *Table 1*. The histogram of 18 case represents a typical tetraploid tumor as shown in *Fig.2*. Case 11 (*Fig.3*) displays a typical aneuploid case lower than tetraploid while case 6 (*Fig.4 a and b*) has two subpopulations with the corresponding cell cycle.

Concerning the AFP, cases 11 and 6 had a slightly elevated level: 19 ng/ml and 21 ng/ml, respectively, while the

others were in normal range. A thorough examination of these two cases – including the process of the whole tumor with serial sections – did not reveal any nonseminomatous component histologically. Unfortunately, the selected 31 pure seminomas were not homogenous concerning the TNM status. Out of these, 21 had $T_1N_0M_0$ status and the rest had metastases, some of them widespreadly. Out of the nine cases with metastases six were aneuploid and three tetraploid. Two patients died, one with widespread metastases, one not in consequence of tumor.

Discussion

The concept of Ewing⁵ and Friedman⁷ that seminoma may act as a common precursor lesion, which may then transform into other forms of germ cell tumor has recently been accepted and confirmed by Oosterhuis and El-Naggar.^{4,11} Although the basis of aneuploidy in different germ cell tumors remains uncertain, polyploidization followed or preceded by gain or loss of chromosomal DNA has been proposed as possible explanation.^{2,5} Findings of others suggest that intratubular germ cell neoplasia has a DI of 2.0 (tetraploid), pure seminoma has a hypotetraploid DI and nonseminomatous germ cell tumors have an aneuploid DI by further loss of genetic material, perhaps loss of suppressor or differentiation genes.^{1,2,4,6,12} Our findings show the same tendency except we found the pure seminomas to be mostly tetraploid. As El-Naggar et al⁴ mentioned in their paper: "the potential source for the lower aneuploidy in other studies could be contamination of non-neoplastic cells in the analysis". In all the previous studies, however, flow cytometry was used. The advantage of image cytometry is that we can select the intact tumor cells and have the possibility to distinguish the mature lymphocytes from other non-neoplastic cells (i.e., fibroblasts and so on). In fact, we measured only mature lymphocytes as control cells to determine the normal diploid value. That can explain why we had

Table 1. DNA ploidy pattern of pure seminomas

| Case no | First or only population | Second population | Case no | First or only population | Second population |
|---------|--------------------------|-------------------|---------|--------------------------|-------------------|
| 1 | 1.96 | – | 17 | 1.82 | – |
| 2 | 2.25 | – | 18 | 1.95 | – |
| 3 | 1.81 | – | 19 | 2.36 | – |
| 4 | 2.18 | – | 20 | 3.25 | – |
| 5 | 1.94 | – | 21 | 1.91 | – |
| 6 | 1.79 | 2.08 | 22 | 1.96 | – |
| 7 | 2.07 | – | 23 | 1.83 | – |
| 8 | 1.76 | 2.16 | 24 | 2.60 | – |
| 9 | 2.17 | – | 25 | 1.98 | – |
| 10 | 1.99 | – | 26 | 1.82 | – |
| 11 | 1.46 | – | 27 | 2.11 | – |
| 12 | 1.86 | – | 28 | 1.56 | – |
| 13 | 2.18 | – | 29 | 2.01 | – |
| 14 | 1.90 | – | 30 | 1.83 | – |
| 15 | 2.14 | – | 31 | 1.86 | – |
| 16 | 1.98 | – | | | |

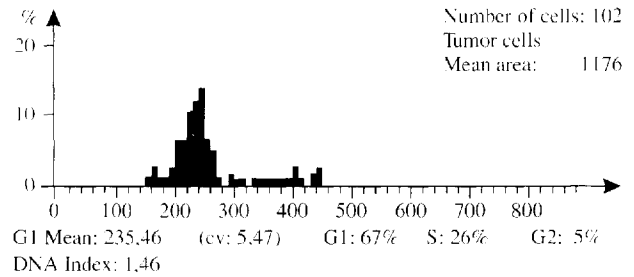
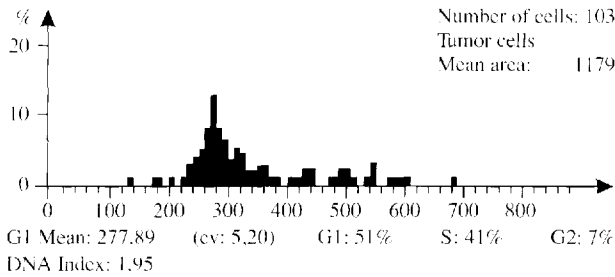
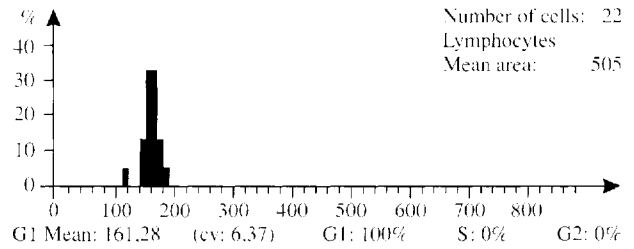
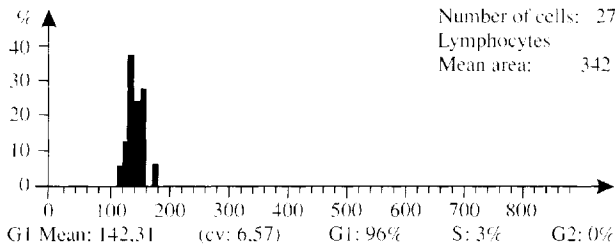


Figure 2. Histogram of case 18. 77.4 % of the tumors displayed similar typical tetraploid pattern.

Figure 3. Histogram of case 11. Clear aneuploid histogram, DI: 1.46. This case had a slightly elevated AFP level, too.

a slightly higher mean DI for seminomas. A further advantage of image cytometry is that one can pick up small subpopulations as in cases 6 and 8. These findings are rather interesting because it seems to offer a direct proof of the loss of chromosomal material. Besides, this case 6 had an elevated AFP level which supports the previously mentioned concept and raises the question of the possibility of nonseminomatous transformation without any morphological evidence.

was not homogenous in this population, it is difficult to evaluate exactly the prognostic importance of DNA-aneuploidy. Nevertheless the six cases with aneuploidy that had metastases underline the distinction between tetraploid and aneuploid cases.

Naturally, we are aware that the low number of our cases is not conclusive. Furthermore, as the TNM status

The "surveillance only" approach (i.e. clinical stage I patients with seminoma need only close follow up after orchietomy and a further treatment reserved only for those who relapse) is gaining nowadays.^{9,10,13} If we accept this approach the so-called contraindicating signs (e.g. the identification of vascular invasion) have an even greater

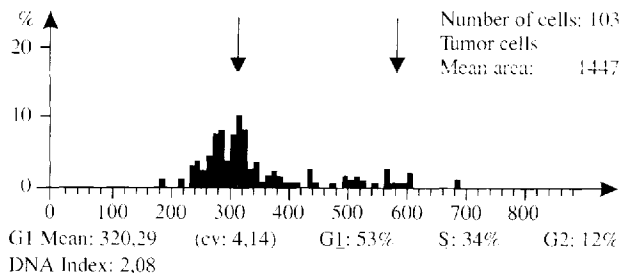
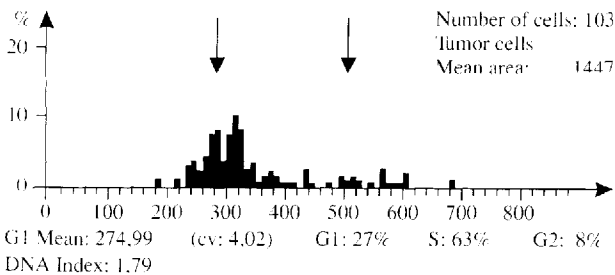
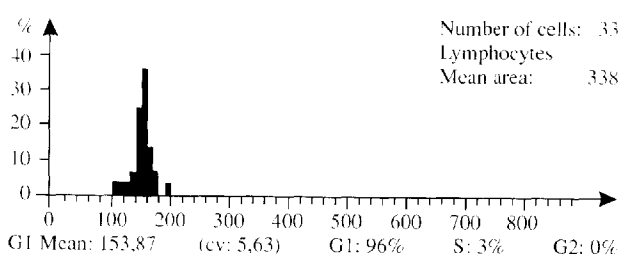
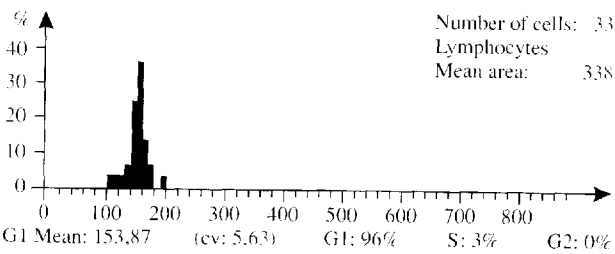


Figure 4 a. and b. Histogram of case 6. Note the two subpopulations (DI: 1,79 and 2,08) with the corresponding cell cycle. This case seems to offer a direct proof of the loss of chromosomal material.

importance. Based on our results and observations we think that aneuploidy (non tetraploid tumors) can be regarded as one of the contraindicating signs for the "surveillance only" approach. On the other hand, a clinical stage I seminoma with typical tetraploid DI can be help in deciding this approach.

References

1. *Atkin NB and Baker MC*: i(12p): specific chromosomal marker in seminoma and malignant teratoma of the testis? *Cancer Genet Cytogenet* 10:199-204, 1983.
2. *Bosl GJ, Demitrovsky E, Reuter VE, Samaniego F, Rodriguez E, Geller NL and Chaganti RSK*: Isochromosome 12: clinically useful marker for male germ cell tumors. *J Natl Cancer Inst* 81:1874-1878, 1989.
3. *Carey F*: Measurement of nuclear DNA content in histological and cytological specimens: principles and applications. *J Pathol* 172:307-312, 1994.
4. *El-Naggar AK, Ro JY, McLemore D, Ayala AG and Batsakis JG*: DNA ploidy in testicular germ cell neoplasms: histogenetic and clinical implications. *Am J Surg Pathol* 16:611-618, 1992.
5. *Ewing J*: Teratoma testis and its derivatives. *Surg Gynecol Obstet* 12:230-261, 1911.
6. *Fossa SD, Nesland JM, Pettersen EO, Amellen O, Waehre H and Heimdal K*: DNA ploidy in primary testicular cancer. *Br J Cancer* 1991;64:948-52.
7. *Friedman NB*: The comparative morphogenesis of extragenital and gonadal teratoid tumors. *Cancer* 4:265-276, 1951.
8. *Hedley DW, Friedlander ML and Taylor JW*: Method for analysis of cellular DNA content of paraffin-embedded pathological material using flow cytometry. *J Histochem Cytochem* 31:1333-1335, 1983.
9. *Marks LB, Rutgers JL and Shipley WU*: Testicular seminoma: clinical and pathological features that may predict para-aortic lymph node metastases. *J Urol* 143:524-527, 1990.
10. *Oliver RT*: Limitations to the use of surveillance as an option in the management of stage I seminoma. *Int J Androl* 10:263-268, 1987.
11. *Oosterhuis JW, Castedo SMMJ, de Jong B, Cornelisse CJ, Dam A, Sleijfer DT and Koops HS*: Ploidy of primary germ cell tumors of the testis. Pathogenetic and clinical relevance. *Lab Invest* 60:14-21, 1989.
12. *Ro JY, Dexeus FH, El-Naggar AK and Ayala AG*: Testicular germ cell tumors: clinically relevant pathologic findings. *Path Ann* 28:58-87, 1991.
13. *Sternberg SS*: Diagnostic surgical pathology. Second Edition, Raven Press, New York, 1994.