

CASE REPORT

Pleomorphic Rhabdomyosarcoma of the Uterus in a Postmenopausal Patient

Katalin BORKA,¹ Kálmán PATAI,² Anikó RENDEK,¹ Gábor SOBEL,² Ferenc PAULIN²

¹2nd Department of Pathology and ²2nd Department of Obstetrics and Gynecology, Semmelweis University, Budapest, Hungary

Pure rhabdomyosarcomas occurring in the adult uterus are very rare, with poor prognosis. We present a case of a 67-year-old woman with postmenopausal vaginal bleeding caused by pleomorphic rhabdomyosarcoma of the uterus, treated with hysterectomy, bilateral salpingo-oophorectomy, pelvic/paraortic lymphadenectomy and partial sig-

moidectomy. Postoperative chemotherapy (Doxorubicin) was given according to protocol. Follow-up examinations one year after surgery revealed no abnormalities or tumor recurrence. The rarity of this histological entity makes the presented case worthy of publication. (Pathology Oncology Research Vol 12, No 2, 102–104)

Key words: pleomorphic rhabdomyosarcoma; uterus; adult; immunohistochemistry; postmenopausal bleeding

Introduction

Pure rhabdomyosarcomas occurring in the uterus of adults are very rare and have poor prognosis. This tumor type usually occurs in infancy or childhood and is referred to as sarcoma botryoides (embryonal), most commonly involving the vagina or cervix. In adults it is usually encountered as a heterologous component of a malignant mixed mesodermal tumor.¹ We present the case of a patient with postmenopausal vaginal bleeding caused by pleomorphic rhabdomyosarcoma without any components of carcinosarcomas or malignant mixed mesodermal tumor. Complete remission was achieved following surgery and chemotherapy.

Case report

A 67-year-old female patient was admitted to our department due to abdominal pain experienced throughout previous months and vaginal bleeding. In her clinical history were four pregnancies (two spontaneous vaginal deliveries and two abortions). She was known to have uterine leiomyoma since 1990. Her menopause started at 54 years of age. In 1990 and 1994 vaginal bleedings were detected, but the histology of

curettings gave negative results. Her past medical history included mild hypertension, irregular heartbeat, cholelithiasis and varicosity. The patient had no history of sexually transmitted diseases, use of oral contraceptives or any other drugs.

Endoscopy, ultrasonography (US) and computerized tomography scan (CT) were performed, revealing a multilobated pelvic mass 15 cm in size, of varying density. Involvement of other organs or lymph nodes was excluded.

Explorative laparotomy revealed a large, irregularly shaped mass approximately 15 cm in diameter, related to the uterus. The partially necrotized tissue, together with a 22-cm-large portion of the adherent sigmoid colon segment, was removed besides total hysterectomy, bilateral salpingo-oophorectomy and pelvic/paraortic lymph node samplings. The patient recovered well and was discharged after 7 days. For postoperative chemotherapy she received 6 cycles Doxorubicin monotherapy every 3 weeks (120 mg total dose/cycles). Follow-up physical examination and CT twelve months after surgery revealed no abnormalities or signs of tumor recurrence.

Pathology findings

Macroscopically, the uterus (485 g, 16x13x10 cm) was partially replaced by multiple necrotic white-brown nodules, which bulged from the serous pelvic surface. Both ovaries and fallopian tubes were infiltrated by the tumor. The neoplasm was attached to the sigmoid colon.

Received: Oct 18, 2005; accepted: March 5, 2006

Correspondence: Katalin BORKA, M.D., 2nd Department of Pathology, Semmelweis University, Üllői út 93., Budapest, H-1091, Hungary. Tel./Fax: +36-1-2156921, E-mail: bk@korp2.sote.hu

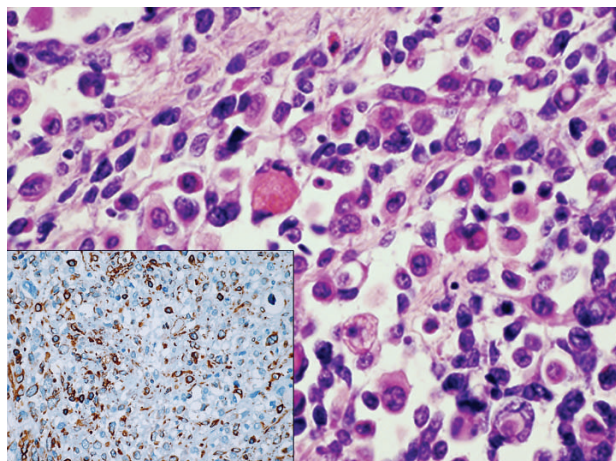


Figure 1. Highly cellular tumor composed of pleomorphic spindle cells and numerous large, sometimes multinucleated, bizarre eosinophilic tumor cells (HE, 1000x). Insert: Immunohistochemistry showed the tumor cells to be positive for vimentin (200x)

Histology of the formalin-fixed, paraffin-embedded, hematoxylin-eosin (HE) stained tumor sections revealed pleomorphic spindle cell sheets, in varying stages of development (*Figure 1*). Numerous plump rhabdomyoblasts with abundant eosinophilic cytoplasm and eccentric nuclei were observed. Many multinucleated tumor giant cells with vesicular nuclei and prominent nucleoli were noticeable. There were extended necrotic areas, located mainly in the centre of the tumor nodules. The tumor infiltrated almost the entire wall, but did not reach the serous surface. The uterine appendices on the right side were extended. The tumor penetrated into the adjacent colon, but the mucosa of the colon showed no signs of tumorous invasion. Cross-striations in the rhabdomyoblasts were proved using phosphotungstic acid-hematoxylin (PTAH) reaction. Immunohistochemical reactions for cytokeratins (AE1/3, CK7, 8, 18, 20), epithelial membrane antigen, CD34, CD68, CD117, synaptophysin, chromogranin, leukocyte common antigen, melan A and α -smooth muscle actin were all found negative. In contrast, antibodies against vimentin (*Figure 1*, inset), desmin (*Figure 2a*), sarcomeric actin and Myf4 (*Figure 2b*) as specific marker of striated muscle cells, reacted with the tumor cells. Specimens prepared from the formalin-fixed material for electron microscopy showed Z-discs and associated actin and myosin filaments. The proliferation index was very high, revealing 20-30 mitoses per 10 high-power fields, which was proved by immunostaining with anti-Ki-67 antibody (*Figure 2c*). Positivity was limited to the poorly differentiated tumor cells. The tumor was negative for estrogen receptor, indicating that it was not hormone-dependent.

The final diagnosis was pure pleomorphic rhabdomyosarcoma, originating from the uterus.

Discussion

Sarcomas of the uterus are usually classified into pure sarcomas, mixed sarcomas and malignant mixed Müllerian tumors. Pure sarcomas have two categories: pure homologous sarcomas including those derived from tissues normally present in the uterus, and pure heterologous sarcomas including those derived from tissues normally not present in the uterus, such as rhabdomyosarcomas, osteosarcomas, chondrosarcomas, and liposarcomas. Mixed sarcomas contain two or more different types of sarcomatous elements. Malignant mixed Müllerian tumors (carcinosarcomas) are a combination of sarcomatous and carcinomatous tissues.²

Over 95% of all uterine sarcomas are malignant mixed Müllerian mesodermal tumors, leiomyosarcomas or endometrial stromal sarcomas. The remaining histological types, including rhabdomyosarcomas, liposarcomas, chondrosarcomas, malignant fibrous histiocytomas, malignant rhabdoid tumors and alveolar soft part sarcomas, have very low incidence (0.05 cases per 100,000 women).¹

Pure rhabdomyosarcomas may occur on the head and neck (24-29%), in the orbita (7-19%), the paratesticular region (20%), other genitourinary (4%) or retroperitoneal (8%) regions, on the extremities (14-23%), or on the trunk (8%). Most cases occur in the first decade of life, but cases involving the paratesticular region and the extremities may also appear in adolescence. Rarely, cases develop congenitally or in adults older than 40 years of age.³

Conventionally, rhabdomyosarcomas are classified as pleomorphic, embryonal, or alveolar sarcomas. Pleomorphic rhabdomyosarcomas are rare, occurring almost exclusively in adults with only isolated cases having been reported in children. Embryonal and alveolar rhabdomyosarcomas arise primarily in children and adoles-

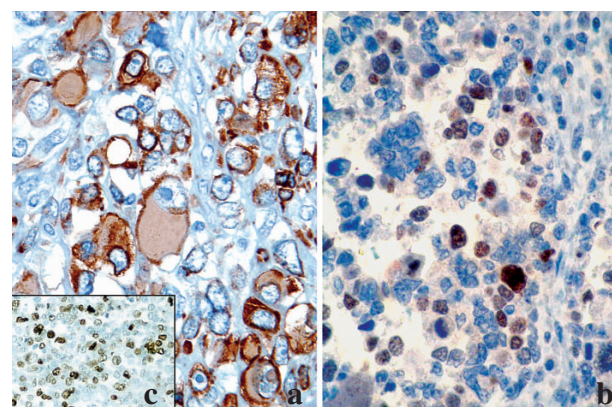


Figure 2a. Tumor cells showing cytoplasmic desmin immunoreaction (1000x). **(b)** Positive Myf4 reaction proved the striated muscle origin of the tumor (400x). **(c)** High proliferative rate detected by Ki-67 antibody (200x)

cents and are therefore grouped under the term „juvenile“. Embryonal types of the tumor are common in the head and neck region, retroperitoneum, bile ducts and the urogenital tract and sometimes even in the extremities. When the tumor forms large polypoid masses it is referred to as the botryoid type. About 25% of the tumors are botryoid tumors, mostly occurring in the genitourinary tract during childhood. Compared with the embryonal type, alveolar rhabdomyosarcomas predominate in the older age group, frequently manifest in adolescents with lesions on the extremities and the trunk.⁴

All three histological types, however, have been described within the uterus. The first rhabdomyosarcoma of the uterus was described by Anderson and Ödmansson in 1869. In the early literature,⁵ some tumors described as pure rhabdomyosarcomas were components of malignant, mixed mesodermal tumors. All pure uterine rhabdomyosarcomas should be extensively sampled (at least one block per cm of tumor) in order to exclude sarcomatous overgrowth in a carcinosarcoma or adenosarcoma.⁶ There are less than 60 cases which are well documented in the literature.⁷

Embryonal rhabdomyosarcomas of the uterus usually involve infants or young children, whereas only a single case of uterine alveolar rhabdomyosarcoma has been described.⁶ Cervical rhabdomyosarcomas are much rarer. In their work, Ng et al mentioned a series of 73 cases compiled in 1987, involving the cervical botryoides variant of embryonal rhabdomyosarcoma.⁸ The literature is mostly made up of pediatric experiences. Hart and Craig described two botryoid embryonal and two pleomorphic rhabdomyosarcomas in adult patients.⁹

The largest published series of uterine pleomorphic rhabdomyosarcomas was eight cases, other accounts were case reports. Pleomorphic rhabdomyosarcomas are usually found in individuals over 45 years of age, but 90% of the other two variants occur before the age of 20. The spindle cell variant of embryonal rhabdomyosarcoma was first reported in 1992 by Cavazzana and coworkers.¹⁰

Numerous theories exist on the origin of these tumors, which could be divided into six groups: (1) metaplasia of tissues normally found in the uterus; (2) origin from occasional striated muscle fibers in the uterus; (3) displacement of mesenchymal cells from the lumbar area along the wolffian ducts, (4) „illegal cell connections“ between the lower pole of the nephroblastem and the caudal mesoderm; (5) displacement along the Müllerian ducts; (6) origin from the mesenchyme of the Müllerian ducts. Origin from undifferentiated elements in the mesenchyme surrounding the Müllerian ducts is regarded as most plausible.⁵ Regarding the etiopathogenesis of pure sarcomas and mixed Müllerian tumors, the role of Tamoxifen used in the treatment of breast cancers should also be mentioned.²

Combined therapy regimens, as chemotherapy, surgery and radiotherapy have resulted in long-term survival in the majority of patients with urogenital rhabdomyosarcomas. Adjuvant chemotherapy with vincristin, actinomycin D and cyclophosphamide (VAC) may also improve survival.¹¹

Differentiated rhabdomyoblasts belonging to the alveolar and pleomorphic subtypes can express CA-125, a specific tumor marker in the serum for non-mucinous epithelial ovarian tumors. This marker can also be shown by immunohistochemistry, though there are literary data where the tumor cells were found negative for CA-125.¹

The neoplasm presented here fulfils the criteria of a pure, pleomorphic rhabdomyosarcoma with the typical histological and immunohistochemical features. The epithelial and heterologous elements were absent, thus carcinosarcoma was excluded. The main symptom was the abnormal uterine bleeding, also noted by others.⁷ Our patient underwent hysterectomy, bilateral adnexectomy and pelvic/para-aortic lymphadenectomy, followed by systemic chemotherapy. No metastases were manifested. Based on the available literature on rhabdomyosarcomas, in particular of the pleomorphic variant, these tumors are very aggressive neoplasms with extremely poor prognosis. One year after surgery, however, our patient is tumor-free, with no detection of any recurrences.

References

1. Holcomb K, Francis M, Ruiz J, et al: Pleomorphic rhabdomyosarcoma of the uterus in a postmenopausal woman with elevated serum CA-125. *Gynecol Oncol* 74: 499-501, 1999
2. Chiarle R, Godio L, Fusi D, et al: Pure alveolar rhabdomyosarcoma of the corpus uteri: description of a case with increased serum level of CA-125. *Gynecol Oncol* 66: 320-323, 1997
3. Sternberg SS (ed.): *Diagnostic Surgical Pathology*. Raven Press, New York, 1989
4. Rosai J (ed.): *Rosai and Ackerman's Surgical Pathology*. Mosby, Edinburgh, 2004
5. Kulka EW, Douglas GW: Rhabdomyosarcoma of the corpus uteri: report of a case, associated with adenocarcinoma of the cervix, with review of the literature. *Cancer* 5: 727-736, 1952
6. McCluggage WG, Lioe TF, McClelland HR, et al: Rhabdomyosarcoma of the uterus: report of two cases, including one of the spindle cell variant. *Gynecol Oncol* 12: 128-132, 2002
7. Podczaski E, Sees J, Kaminski P, et al: Rhabdomyosarcoma of the uterus in a postmenopausal patient. *Gynecol Oncol* 37: 439-442, 1990
8. Ng TY, Loo KT, Leung TW, et al: Alveolar rhabdomyosarcoma of the cervix. *Gynecol Oncol* 91: 623-626, 2003
9. Hart WR, Craig JR: Rhabdomyosarcomas of the uterus. *Am J Clin Pathol* 70: 217-223, 1987
10. Cavazzana AO, Schmidt D, Ninfo V, et al: Spindle cell rhabdomyosarcoma: a prognostically favorable variant of rhabdomyosarcoma. *Am J Surg Pathol* 16: 229-235, 1992
11. Montag TW, D'ablaing G, Schlaerth JB, et al: Embryonal rhabdomyosarcoma of the uterine corpus and cervix. *Gynecol Oncol* 25: 171-194, 1986